

Low-grade Appendiceal Mucinous Neoplasm Masquerading as Acute Appendicitis: A Case Report

PV NIKHIL¹, JESSICA MINAL², BHARGAVI KALBURGI NAGABHUSHAN³, NIRUPAMA MURALI⁴

(CC) BY-NC-ND

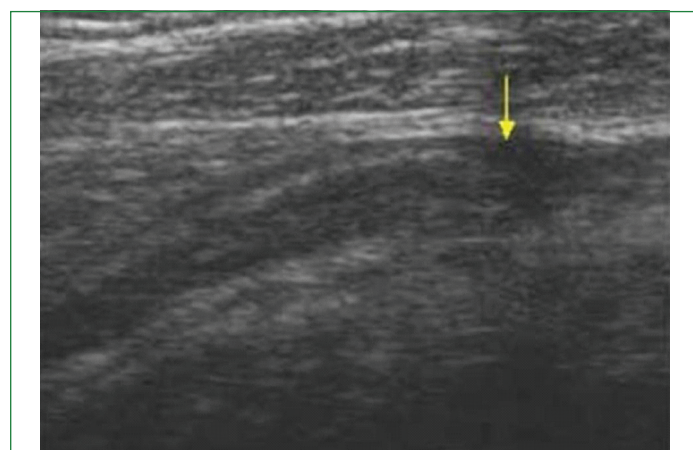
ABSTRACT

Appendiceal mucinous neoplasms, particularly Low-grade Appendiceal Mucinous Neoplasms (LAMN), are rare but important diagnostic entities as they are potential causes of a surgical abdomen. The clinical manifestations of this lesion are obscure and ill-defined, and these lesions are commonly misdiagnosed as acute appendicitis, adnexal masses, or retroperitoneal tumours. This lesion can rupture and seed mucin and neoplastic epithelium into the peritoneum, leading to Pseudomyxoma Peritonei (PMP), a serious complication with a high morbidity and mortality rate. Therefore, timely identification and treatment of LAMN are crucial for reducing the risk of PMP and improving prognosis and outcomes. Ultrasonography (USG) and Computed Tomography (CT) scans are useful methods for diagnosis; however, the diagnosis is often incidental or found intraoperatively during resection for suspected acute appendicitis. Clinical awareness of the misleading presentations of LAMN should be present in cases of a surgical acute abdomen to prevent performing a dissimilar treatment intervention. Considering the rarity of this lesion and its varied presentation, it is important to study and document this type of neoplasia in the literature. Hereby, authors report a rare case of LAMN in a 33-year-old male patient with a primary diagnosis of acute appendicitis. This case highlights the importance of having a high index of clinical suspicion of appendiceal malignancy and mucocoele rupture in patients planned for appendectomy. This also emphasises the fact that all excised appendectomy tissues should be sent for histopathological examination as they can harbor pathological changes like LAMN.

Keywords: Acute abdomen, Appendix, Mucocoele, Pseudomyxoma peritonei

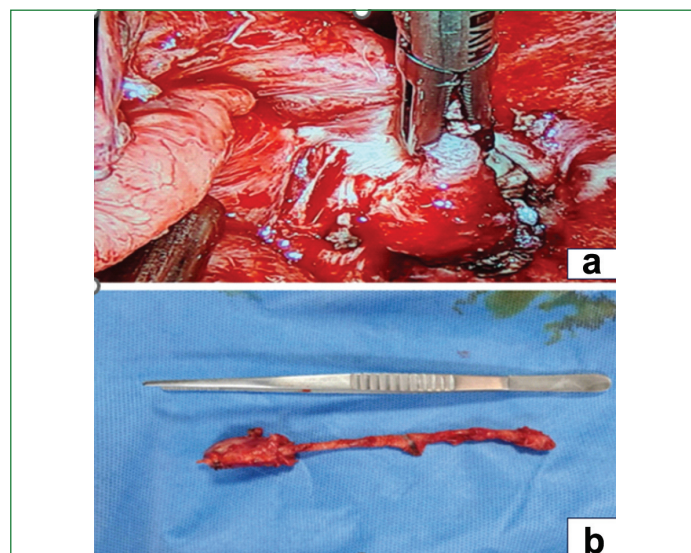
CASE REPORT

A 33-year-old male presented to the emergency department with abdominal pain that had started four days prior to admission. The pain was sudden in onset, intermittent, and colicky in nature, mainly in the lower abdomen. The patient had no significant past medical history and no history of abdominal trauma. He was non diabetic and normotensive. On general physical examination, the patient was moderately built and nourished with stable vital signs. Clinical and physical examination revealed tenderness in the right iliac fossa with absence of signs of acute obstruction, and a provisional diagnosis of acute appendicitis was made. Laboratory investigations revealed a mildly elevated total leukocyte count (11,480/cumm) with a normal differential count (Neutrophils-65%, Lymphocytes-30%, Monocytes-3%, and Eosinophils-2%). Other parameters were within normal limits. The USG of the abdomen showed a distended and inflamed appendix with minimal fluid in the right iliac fossa [Table/Fig-1].



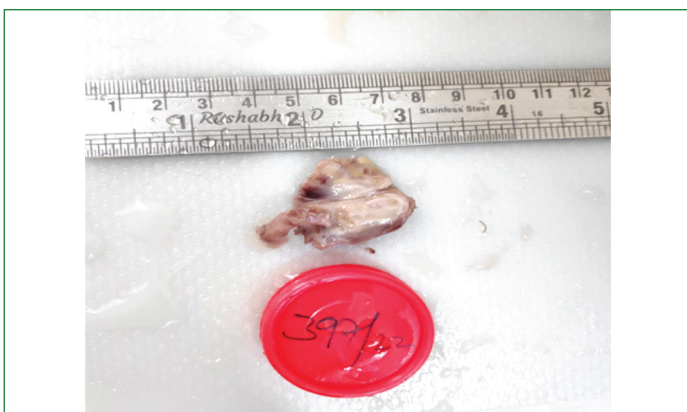
[Table/Fig-1]: Ultrasound (USG) abdomen showed a distended and inflamed appendix with minimal fluid in right iliac fossa.

The patient underwent emergency appendicectomy. Intraoperatively, dense adhesions to the anterior abdominal wall [Table/Fig-2a] and an appendicular mass at the tip of the appendix were observed [Table/Fig-2b]. Based on the intraoperative findings, the surgeon made a differential diagnosis of an inflammatory lesion and appendicular malignancy.



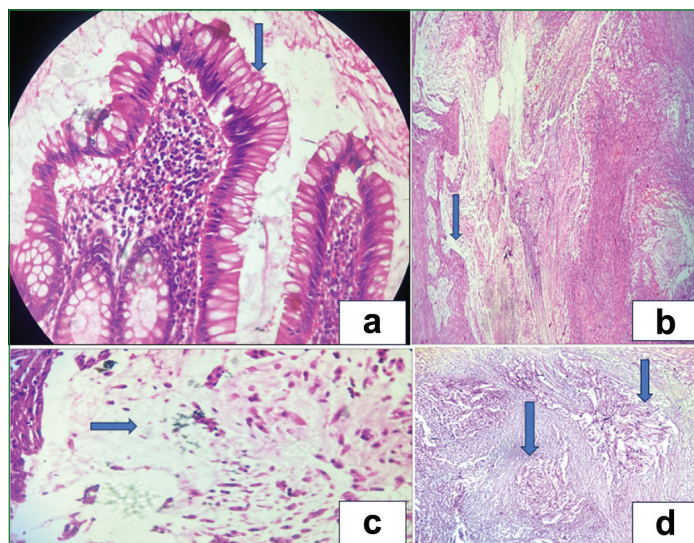
[Table/Fig-2]: Intraoperative findings: a) Dense adhesions in the abdomen; b) Appendicular mass at the tip of appendix.

The appendix was excised and sent for histopathological examination. The gross specimen was partially dilated, sent in two pieces together measuring 9 cm in length. The external surface showed a distended portion of the distal half of the appendix with congested blood vessels and a grey-white mass measuring 3×3×1 cm. The cut section revealed an obliterated lumen, with the wall of the appendix thickened and mucoid areas in the distal half corresponding to the distended portion on the outer surface. The rest of the appendix was unremarkable [Table/Fig-3].



[Table/Fig-3]: Grey-white mass in the distal end of appendix with mucoid areas in the thickened wall.

Representative sections were taken and stained with Haematoxylin and Eosin (H&E) stain. The serial sections studied showed focal areas of mucosal proliferation with occasional villi lined by tall columnar cells with basal compressed nuclei and apical mucin. Broad mucin pools dissecting the muscular layer with a foreign body giant cell reaction to the mucin were also noted [Table/Fig-4a-c]. The mucin pools were Periodic Acid-Schiff (PAS) positive; however, tumour cells were absent in mucin pools, ruling out the possibility of mucinous adenocarcinoma [Table/Fig-4d]. A diagnosis of LAMN of the distal appendix with a pathological stage of pTis (LAMN) confined by the muscularis propria as per the American Joint Committee on Cancer staging (AJCC) 8th edition was rendered [1].



[Table/Fig-4]: Microscopy. a) Mucosal proliferation with columnar cells showing basal nuclei and apical mucin (H&E, 40X); b) Broad mucin pools dissecting the muscular layer (H&E, 4X); c) High power view of the broad mucin pools (H&E, 40X); d) PAS positive mucin pools (PAS stain, 4X).

The postoperative period was uneventful, and the patient was discharged with advice for follow-up to avoid the rare possibility of developing PMP. The patient was followed-up for a period of six months in the outpatient clinic without any significant complaints, after which he was lost to follow-up.

DISCUSSION

Tumours of the appendix are the rarest to occur, found in 1% of appendectomy specimens and account for only 1% of all intestinal neoplasms [2,3]. The most common tumour of the appendix is carcinoids, comprising 40 to 50% of appendiceal tumours. Mucinous neoplasms of the appendix are the rarest of all, accounting for less than 1% of all appendiceal tumours and have varying malignant potential [4-6]. The histopathological classification, diagnostic criteria, clinical outcomes, and prognosis have always been controversial. Different terminologies were defined and classified by the World Health Organisation (WHO), such as mucocele and mucinous

cystadenoma [7]. However, in 2010, the WHO reached a consensus and stabilised the evolving nomenclature controversy regarding the classification of PMP and associated appendiceal neoplasia, replacing the term “mucinous cystadenomas” with the new term “LAMN” [7-9]. This improved the cytoarchitectural classification to streamline accurate diagnosis and enable appropriate treatment modalities [8]. In 2016, a consensus regarding the classification of PMP and associated appendiceal neoplasia continued to use the new term “LAMN” in place of the term “mucinous cystadenomas”. Additionally, the term “High-grade Appendiceal Mucinous Neoplasm-HAMN” was suggested to describe non infiltrative invasive lesions with high-grade cytologic atypia [10,11]. These terms LAMN and HAMN have been retained without any further change in the latest 2019 WHO classification for appendiceal mucinous lesions [9].

LAMN is a rare heterogeneous disease characterised by mucosal proliferation in the appendix with uncertain malignant potential [6]. The peak age of onset is between 50 and 60 years with a female preponderance [5,12]. However, Al Laham O et al., suggested that both males and females are at similar risk of developing appendiceal mucinous cell neoplasms [13]. This was substantiated by Saleem N et al., as they suggested that these lesions are commonly diagnosed in men, particularly in the sixth decade [10]. It is an uncommon lesion that can be found during evaluation for unrelated complaints and can present with abdominal pain, vomiting, distention, palpable mass, intestinal obstruction, weight loss, and intussusception [14-16]. This condition can be either an incidental intraoperative finding or present with right lower quadrant symptoms seen in acute appendicitis, such as right iliac pain, fever, and vomiting, or rarely with symptoms of PMP [15,17]. Carr NJ and Sobin LH reported that 32% of patients with appendiceal neoplasms received a preoperative diagnosis of acute appendicitis, while 23% were diagnosed incidentally [18]. In the current case scenario, the patient was a 33-year-old male with right quadrant pain mimicking the pain of acute appendicitis. These symptoms are actually due to distention of the appendix by intraluminal mucin accumulation, which is called mucocele [19].

LAMN is also associated with diverticula, herniations, dissections, and may be complicated by spontaneous or iatrogenic rupture, resulting in pseudomyxoma or distant metastasis of the abdominal wall, which can be life-threatening [16,20]. In the present case as well, the patient was taken for surgery with a preoperative diagnosis of acute appendicitis, and an emergency appendectomy was performed. Nevertheless, the ideal treatment of LAMN restricted to the appendix is right hemicolectomy, and for LAMN with peritoneal seeding, cytoreductive surgery and hyperthermic intraperitoneal chemotherapy are recommended. Hence, a preoperative misdiagnosis of acute appendicitis hampers the surgical treatment, restricting it to a simple appendectomy [21].

Imaging modalities for diagnosis include USG and CT, with CT being the most regularly used radiographic interpretation for accurate preoperative diagnosis [7]. Abdominal USG shows a distended cystic appendix with porcelain wall calcification and a lamellated mucinous “onion-skin” appearance; rupture will show an interruption in the appendiceal wall with leakage. CT can show an enlarged appendix with wall calcifications and thickening, and additionally demonstrate septations, calcified nodules, and liver margin scalloping in PMP [16].

Grossly, LAMN may appear unremarkable or demonstrate the distension of the appendix because of abnormal accumulation of mucin in the lumen. There can be thickening of the appendiceal wall due to inflammation and fibrosis or gross perforations with mucin extrusion into the serosa [8,10]. Histopathological findings of LAMN can take several forms, with the classic presentation being the replacement of normal appendiceal mucosa with a filiform villous or flat mucinous epithelial proliferation showing features of low-grade atypia, such as columnar cells with tall intracytoplasmic mucin vacuoles compressing the bland-looking nucleus. The wall can exhibit varying degrees of fibrosis and hyalinisation with dissecting mucin

pools devoid of any tumour cells [11,16]. In this case, focal areas of mucosal proliferation with occasional villi lined by tall columnar cells with basal compressed nuclei and apical mucin were observed, along with broad mucin pools dissecting the muscular layer.

According to research by Misdraji J et al., no recurrence was seen in patients with LAMNs confined to the appendix, whereas the 3-year, 5-year, and 10-year survival rates in LAMNs with extra-appendiceal spread were 100%, 86%, and 45%, respectively [22]. Clinical follow-up of patients with LAMN is an important aspect that necessitates radiographic imaging every six months post-appendectomy for two years for adequate monitoring of tumour recurrence and complications associated with PMP [8]. For patients at high-risk of disease progression, follow-up should continue for the first five years after the diagnosis of LAMN [3].

CONCLUSION(S)

LAMN is a rare lesion with varied clinical presentations. Such lesions need to be documented in the literature to raise clinical awareness of a possible appendiceal malignancy and mucocoele rupture in patients planned for appendectomy for acute appendicitis. This also underscores the importance of sending all excised appendectomy tissues for histopathological examination, as they can harbour pathological changes like LAMN. The role of histopathology is undisputed in diagnosing and staging these lesions, requiring a high index of suspicion due to the lack of cytological atypia. Additionally, this article emphasises the importance of choosing the appropriate preoperative radiological modality and surgical or medical treatment modality to prevent recurrence and the subsequent development of PMP.

Acknowledgement

Authors would like to acknowledge and thank the faculty from Department of Surgery.

REFERENCES

- [1] Amin MB, Edge S, Greene F, Byrd DR, Brookland RK, Washington MK, et al. (Eds.). AJCC Cancer Staging Manual (8th edition). Springer International Publishing: American Joint Commission on Cancer; 2017 [cited 2016 Dec 28].
- [2] Connor SJ, Hanna GB, Frizelle FA. Appendiceal tumors: Retrospective clinicopathologic analysis of appendiceal tumors from 7,970 appendectomies. *Dis Colon Rectum*. 1998;41(1):75-80. Doi: 10.1007/BF02236899. PMID: 9510314.
- [3] Ramaswamy V. Pathology of mucinous appendiceal tumors and pseudomyxoma peritonei. *Indian J Surg Oncol*. 2016;7(2):258-67. Doi: 10.1007/s13193-016-0516-2. Epub 2016 Mar 19. PMID: 27065718; PMCID: PMC4818623.
- [4] Deng K, Zhang CQ, Wang GL, Li W. Primary appendiceal mucinous adenocarcinoma mimicking bladder carcinoma: A case report and review of the literature. *Oncol Lett*. 2014;7(4):1270-72. Doi: 10.3892/ol.2014.1842. Epub 2014 Jan 30. PMID: 24944705; PMCID: PMC3961443.
- [5] Yu XR, Mao J, Tang W, Meng XY, Tian Y, Du ZL. Low-grade appendiceal mucinous neoplasms confined to the appendix: Clinical manifestations and CT findings. *J Investig Med*. 2020;68(1):75-81. Doi: 10.1136/jim-2018-000975. Epub 2019 Jul 11. PMID: 31300469; PMCID: PMC6996116.
- [6] Shaib WL, Assi R, Shamseddine A, Alese OB, Staley C 3rd, Memis B, et al. Appendiceal mucinous neoplasms: Diagnosis and management. *Oncologist*. 2018;23(1):137. Doi: 10.1634/theoncologist.2017-0081.
- [7] Rabie ME, Al Shraim M, Al Skaini MS, Alqahtani S, El Hakeem I, Al Qahtani AS, et al. Mucus containing cystic lesions "mucocoele" of the appendix: The unresolved issues. *Int J Surg Oncol*. 2015;2015:139461. Doi: 10.1155/2015/139461. Epub 2015 Mar 23. PMID: 25878899; PMCID: PMC4386699.
- [8] Gonzalez HH, Herard K, Mijares MC. A rare case of low-grade appendiceal mucinous neoplasm: A case report. *Cureus*. 2019;11(1):e3980. Doi: 10.7759/cureus.3980. PMID: 30967980; PMCID: PMC6440557.
- [9] Koç C, Akbulut S, Akatlı AN, Türkmen Şamdanlı E, Tuncer A, Yılmaz S. Nomenclature of appendiceal mucinous lesions according to the 2019 WHO Classification of tumors of the digestive system. *Türk J Gastroenterol*. 2020;31(9):649-57. Doi: 10.5152/tjg.2020.20537. PMID: 33090102; PMCID: PMC7577417.
- [10] Saleem N, Shahid F, Ali SM, Rashid S, Al-Taraki M, Sameer M. Incidental low-grade mucinous neoplasm of appendix in pregnancy: A case report & literature review. *Ann Med Surg (Lond)*. 2020;59:195-98. Doi: 10.1016/j.amsu.2020.10.004. PMID: 33204412; PMCID: PMC7647936.
- [11] Perivoliotis K, Christodoulidis G, Samara AA, Sgantzou IK, Floros T, Volakakis G, et al. Low-Grade Appendiceal Mucinous Neoplasm (LAMN) primarily diagnosed as an ovarian mucinous tumor. *Case Rep Surg*. 2021;2021:5523736. Doi: 10.1155/2021/5523736. PMID: 33976950; PMCID: PMC8084675.
- [12] Chen W, Ye JW, Tan XP, Peng X, Zhang Y, Liang JL, et al. A case report of appendix mucinous adenocarcinoma that recurred after additional surgery and a brief literature review. *BMC Surgery*. 2020;20(1):01-04.
- [13] Al Laham O, Albrijawy R, Adi A, Al Kurdi MF, Atia F, Hamed H. A rare case of a low-grade appendiceal mucinous neoplasm in a 46-year-old middle eastern female- A case report. *Int J Surg Case Rep*. 2022;93:106997. Doi: 10.1016/j.ijscr.2022.106997. Epub 2022 Mar 30. PMID: 35366611; PMCID: PMC8976147.
- [14] Gupta P, Mishra AK, Deo A, Yadav R, Milan KC, Bhattarai A. Complete small intestinal obstruction due to band formation in low-grade appendiceal mucinous neoplasm: A rare case report and literature review. *Int J Surg Case Rep*. 2023;108:108422. Doi: 10.1016/j.ijscr.2023.108422. Epub 2023 Jun 17. PMID: 37348199; PMCID: PMC10382774.
- [15] Maloku H. A rare case report: Low-grade appendiceal mucinous neoplasm (LAMN) located under the left costal margin, the gastric level and the transverse colon. *J Surg Case Rep*. 2023;2023(5):rjad234. Doi: 10.1093/ijscr/rjad234. PMID: 37153824; PMCID: PMC10156431.
- [16] Wang AS, Ismael HN, Parikh J, Modesto VL. Low-grade appendiceal mucinous neoplasm: A case series. *Cureus*. 2022;14(9):e28755. Doi: 10.7759/cureus.2875.
- [17] Alghamdi AO, Aldossary MY, Alsawidan M, AlBahar S. Low-grade appendiceal mucinous neoplasm mimicking an ovarian cyst: A case report. *Int J Surg Case Rep*. 2020;70:145-48. Doi: 10.1016/j.ijscr.2020.04.074. Epub 2020 May 7. PMID: 32422578; PMCID: PMC7229422.
- [18] Carr NJ, Sobin LH. Adenocarcinoma of the appendix. In: Bosman FT, Carneiro F, Hruban RH, Theise ND, editors. WHO Classification of Tumours of the Digestive System, World Health Organization Classification of Tumours. Lyon: IARC Press; 2010. pp. 122-25.
- [19] Mastoraki A, Sakorafas G, Vassiliou P, Contopoulou C, Arkadopoulos N. Mucocoele of the appendix: Dilemmas in differential diagnosis and therapeutic management. *Indian Journal of Surgical Oncology*. 2016;7(1):86-90.
- [20] Xu R, Yang ZL. Treatment of a giant low-grade appendiceal mucinous neoplasm: A case report. *World J Clin Cases*. 2021;9(35):11056-60. Doi: 10.12998/wjcc.v9.i35.11056. PMID: 35047618; PMCID: PMC8678861.
- [21] Tiselius C, Kindler C, Shetye J, Letocha H, Smedh K. Computed tomography follow-up assessment of patients with low-grade appendiceal mucinous neoplasms: Evaluation of risk for pseudomyxoma peritonei. *Ann Surg Oncol*. 2017;24(7):1778-82. Doi: 10.1245/s10434-016-5623-3. Epub 2017 May 4. PMID: 28474197.
- [22] Misdraji J, Yantiss RK, Graeme-Cook FM, Balis UJ, Young RH. Appendiceal mucinous neoplasms: A clinicopathologic analysis of 107 cases. *Am J Surg Pathol*. 2003;27(8):1089-103. Doi: 10.1097/00000478-200308000-00006. PMID: 12883241.

PARTICULARS OF CONTRIBUTORS:

1. Assistant Professor, Department of Pathology, Dr. Chandramma Dayananda Sagar Institute of Medical Education and Research, Dayananda Sagar University, Harohalli, Karnataka, India.
2. Associate Professor, Department of Pathology, Dr. Chandramma Dayananda Sagar Institute of Medical Education and Research, Dayananda Sagar University, Harohalli, Karnataka, India.
3. Junior Consultant, Department of Pathology, Trident Diagnostics and Healthcare Pvt. Ltd., Bengaluru, Karnataka, India.
4. Professor and Head, Department of Pathology, Dr. Chandramma Dayananda Sagar Institute of Medical Education and Research, Dayananda Sagar University, Harohalli, Karnataka, India.

NAME, ADDRESS, E-MAIL ID OF THE CORRESPONDING AUTHOR:

Dr. Jessica Minal,
Associate Professor, Department of Pathology, Dr. Chandramma Dayananda Sagar Institute of Medical Education and Research, Dayananda Sagar University, Ramanagara, Harohalli-562112, Karnataka, India.
E-mail: jes.minal@gmail.com

AUTHOR DECLARATION:

- Financial or Other Competing Interests: None
- Was informed consent obtained from the subjects involved in the study? No
- For any images presented appropriate consent has been obtained from the subjects. No

PLAGIARISM CHECKING METHODS: [Jain H et al.]

- Plagiarism X-checker: Oct 27, 2023
- Manual Googling: Feb 01, 2024
- iThenticate Software: Feb 24, 2024 (20%)

ETYMOLOGY: Author Origin

EMENDATIONS: 6

Date of Submission: **Oct 26, 2023**

Date of Peer Review: **Jan 06, 2024**

Date of Acceptance: **Feb 26, 2024**

Date of Publishing: **Jul 01, 2024**