

Xanthogranulomatous Orchitis Mimicking a Testicular Malignancy: A Rare Case with Brief Review of Literature

BHUVAN ADHLAKHA¹, PRIYANKA GOGOI², PREETI DIWAKER³, PRIYA YADAV⁴, ANIL SINGH⁵

CC BY-NC-ND

ABSTRACT

Xanthogranulomatous Orchitis (XGO) is a rare, distinct type of chronic inflammation causing destruction of the tissue by infiltrate of lipid laden macrophages. It is commonly seen in the gall bladder, kidney and is rarely reported in the testis. Authors hereby report case of a 32-year-old male who presented with a swelling in the right testis since three weeks. On clinical examination, ultrasound findings, a provisional diagnosis of testicular neoplasm was made. Simple right orchidectomy was performed and on histopathological examination the testis was found to be replaced with large lipid laden macrophages (Xanthoma cells) along with lymphocytes, foci of necrosis and haemorrhage, a diagnosis of XGO was rendered. The preoperative diagnosis of XGO is very challenging as the condition often mimics a testicular neoplasm, thus the final diagnosis relies on the histopathological examination. Extensive sampling of the tissue should be done to rule out any concurrent testicular neoplasm.

Keywords: Testicles, Testis swelling, Xanthogranulomatous inflammation

CASE REPORT

A 32-year-old male presented with painful swelling in the right testis since three weeks. He had no history of trauma, urinary tract infection, any chronic illness or any family history. Patient was on oral antibiotics for two weeks but showed no improvement. His complete blood count, blood urea, random blood sugar, tumour markers such as alpha-fetoprotein, Beta-Human Chorionic Gonadotropin (β -HCG), and lactate dehydrogenase were within normal range. Scrotal ultrasonography revealed a heterogeneous avascular mass measuring 7×3.8×2.5 cm in the right hemiscrotum.

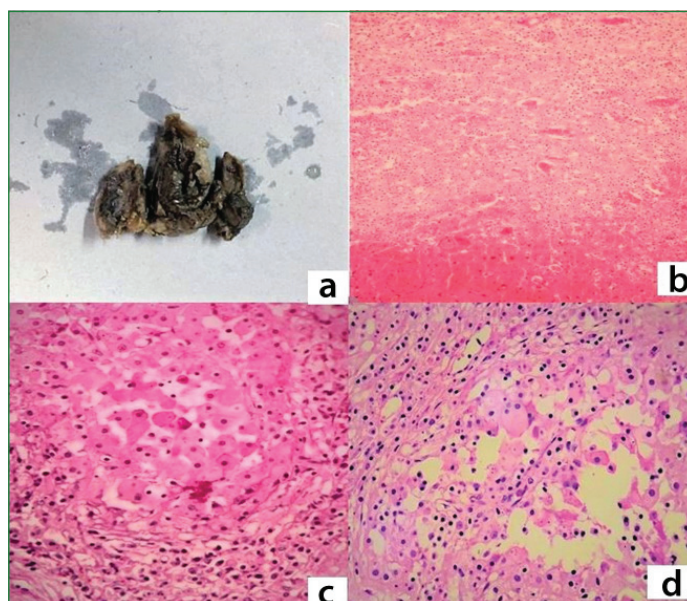
The clinical differential diagnosis thought was ranging from an infective cause, granulomatous diseases of the testis, malakoplakia and testicular neoplasm. Amongst the differentials considered only an infective cause can show treatment with antibiotics and rest all the differentials require a mandatory exploration of the testis. A simple right orchidectomy was planned, on surgical exploration the right testis was found to be liquefied with a thickened testicular covering and the tissue was sent for histopathological examination.

Grossly, the testis measured 7.5×4×2.5 cm and spermatic cord measured 1.8 cm. Cut section showed an ill-defined necrotic mass replacing the entire testis [Table/Fig-1a]. Microscopy revealed complete replacement of the testis by sheets of macrophages having abundant foamy cytoplasm (Xanthoma cells) intermingled with lymphocytes along with few foci of necrosis and haemorrhage [Table/Fig-1b-d].

No epithelioid cell granulomas were identified. The histopathological differential diagnosis considered were XGO, malakoplakia, leprosy and tuberculosis. Special stains including Periodic Acid Schiff, Gomori methanamine silver and Ziehl-Neelsen stains were done to rule out Michaelis Guttman bodies, fungi and acid-fast bacilli respectively and were negative. Based on these findings a diagnosis of XGO was offered. The postoperative course of the patient was uneventful and the follow-up period was almost a year.

DISCUSSION

Xanthogranulomatous inflammation (XGI) is a rare, distinct type of chronic inflammation characterised by destruction of tissue by dense infiltrate of lipid laden macrophages [1]. Kidney and gall



[Table/Fig-1]: a) Gross photograph showing ill-defined necrotic mass replacing the entire testis. b) Microphotograph showing replacement of testis by sheets of macrophages with abundant foamy macrophages i.e., the xanthoma cells along with area of necrosis and haemorrhage (H&E, 40x). c) Microphotograph showing large lipid laden macrophages (xanthoma cells) along with lymphoplasmacytic inflammatory infiltrate (H&E, 400X). d) Microphotograph showing large lipid laden macrophages (xanthoma cells) (H&E, 400X).

bladder are the most commonly affected organs followed by liver, appendix, ovary, vagina, bone, urinary bladder and rarely affects prostate, epididymis and testis [2-4].

To the best of our knowledge, 28 cases of XGO have been reported till date and are summarised in [Table/Fig-2] [1-21]. Out of the 28 cases of XGO, left testis was involved in 19 (67.8%) cases, right testis was involved in 8 (28.5%) cases whereas bilateral testicular involvement was reported in only one case [5]. In the present study, right testis was involved and left testis was unremarkable clinically.

Out of the 28 cases, 13 (46.4%) had no associated condition, similar to present case, whereas 7 (25%) cases gave history of diabetes. A rare occurrence of XGO and with an occult seminoma has been reported by Val-Bernal JF et al., in 2010 [13].

S. No.	Study	Age (years)	Laterality	Associated condition	Clinical presentation/Provisional diagnosis
1.	Wiener LB et al., [5] (1987)	60	Bilateral	Diabetes	Bilateral testicular abscess
2.	Usamentiaga E et al., [6] (1998)	35	Left	None	Testicular neoplasm
3.	Vaidyanathan S et al., [7] (2000)	21	Left	Neuropathic bladder	Epididymo-orchitis
4.	Hajri M et al., [8] (2001)*	30-75	Left-5 Right-2	Diabetes-3 TURP- 2 Neuropathic bladder- 1 None -1	Epididymo-orchitis
5.	Yap RL et al., [9] (2004)	64	Left	None	Testicular neoplasm
6.	Nistal M et al., [2] (2004)	58	Left	Diabetes	-
		79	Left	NA	Testicular abscess
7.	Demirci D et al., [10] (2004)	21	Left	Fistula	Testicular tumour
8.	Salako AA et al., [11] (2006)	24	Left	None	Testicular tumour
9.	Al-Said S et al., [1] (2007)	44	Right	None	
10.	Rifat Mannan AA et al., [12] (2009)	65	Left	Diabetes	Malignancy
11.	Val-Bernal JF et al., [13] (2010)	52	Left	Occult seminoma	Testicular neoplasm
12.	Repetto P et al., [14] (2012)	13	Left	None	Neoplasm like lesion
13.	Ezer SS et al., [15] (2013)	14	Right	None	
14.	Alazab RS et al., [3] (2017)	69	Right	None	Neoplasm /Inflammatory reaction
15.	Yamashita S et al., [16] (2017)	28	Left	Blunt Trauma	Benign tumour Epidermoid cyst
16.	Somani K et al., [4] (2019)	20	Left	None	Testicular malignancy
17.	Hama Amin Said et al., [17] (2019)	70	Right	H/o TURP	
18.	Sharma P et al., [18] (2019)	60	Left	None	Testicular tumour
19.	Gongora E Silva RF et al., [19] (2019)	55	Right	Diabetes	Testicular torsion
20.	Verma R et al., [20] (2020)	50	Right	None	Scrotal abscess
21.	Murshed KA et al., [21] (2020)	49	Left	None	-
22.	Present study, 2022	32	Right	None	Testicular neoplasm

[Table/Fig-2]: Summary of clinical presentation of 28 cases of XGO [1-21].

* N:7; TURP: Transurethral resection of the prostate

The XGO is most commonly encountered between 3rd and 7th decade of life similar to present case [20]. The youngest case of XGO reported till date is of a 13-year-old boy by Repetto P et al., in 2012 [14].

Out of the 28 cases, 11 (39.2%) had a provisional diagnosis or clinical presentation of a testicular neoplasm similar to present case. XGO often mimics testicular tumours as there are no specific findings that distinguish it from testicular malignancy. Tumour markers are usually helpful in differentiating but sometimes problem persists because few testicular tumours may not be positive for serologic markers [12].

Aetiopathogenesis: The pathogenesis of XGO is not well established; however, multiple factors have been hypothesised by numerous studies [6-19]. The most advocated explanation is persistent chronic inflammation in the presence of obstruction of the epididymis or urinary obstruction [3]. Abnormal lipid metabolism, congenital anomalies, immunological defects in macrophages, lymphatic dysfunction and persistent urinary tract infection are certain other reported influencing factors [12,19]. In older patients, it has been reported to occur due to testicular ischemia secondary to atherosclerosis and in endarteritis or endophlebitis in younger patients [15].

Various studies have postulated that the most possible infective agent implicated with XGO is *E. coli* [2,8,12]. In most cases, culture often yields a negative result and the failure to identify any infective agent may be related to the chronicity of inflammation and the prior use of antibiotic in most cases [12].

On gross examination, the tissue may show grey yellow areas denoting the lipid content and it might also show ill formed necrotic areas or mass due to the destruction of the tissue by the chronic inflammation, similar to our case. Microscopy shows nodules of lipid laden macrophages with presence of lymphocytes, giant cells and necrosis, similar to present case. However, these findings are not specific to XGI and may also be seen in tumours [19].

Differential diagnosis: The clinical diagnosis of XGO is difficult as it mimics conditions ranging from infections to the testicular malignancy. The main differentials are infectious epididymo-orchitis (usually caused by anaerobic bacteria and improves on antibiotic therapy); malakoplakia (an uncommon granulomatous disease of the testis showing presence of characteristic intracytoplasmic inclusions known as Michaelis Gutmann bodies); Rosai-Dorfman disease (an inflammatory condition of the testis showing lymphocytes, plasma cells and sheets of pale staining histiocytes showing emperipolesis) [1,4,17,18].

As discussed above, XGO often mimics testicular tumours, as there are no specific findings that distinguish it from testicular malignancy [12]. An important point to note is that XGO may co-exist with a testicular malignancy. The diagnostic utilities of inguinal ultrasound, Computed Tomography (CT) scan, fine needle aspiration cytology, serologic tumour makers and clinical history are very limited. Histopathology remains the cornerstone for diagnosing xanthogranulomatous epididymo-orchitis [20].

Treatment: Due to the wide destructive nature of XGO, a radical or partial orchidectomy is the treatment of choice. In the present case-simple orchidectomy was done. Transinguinal route is the preferred approach but in conditions such as testicular abscess or in presence of scrotal discharging sinuses-scrotal route is preferred and hemiscrotectomy is also performed. Antibiotic therapy also plays some role due to the presence of anaerobic bacteria [18,19].

CONCLUSION(S)

The XGO should always be kept in mind as one of the differentials in mind while dealing with a testicular swelling mimicking a testicular malignancy. Histopathology remains the gold standard for diagnosing this condition as the other diagnostic modalities are not of much helping making the preoperative diagnosis.

REFERENCES

- [1] Al-Said S, Ali A, Alobaidy AK, Mojeeb E, Al-Naimi A, Shokeir AA. Xanthogranulomatous orchitis: Review of the published work and report of one case. *Int J Urol.* 2007;14(5):452-54.
- [2] Nistal M, Gonzalez-Peramato P, Serrano A, Regadera J. Xanthogranulomatous funiculitis and orchiepididymitis: Report of 2 cases with immunohistochemical study and literature review. *Arch Pathol Lab Med.* 2004;128(8):911-14.
- [3] Alazab RS, Ghawanmeh HM, Al-Okour RK, Alshammari A, Lafi T, Al-Karasneh AI, et al. Xanthogranulomatous Orchitis: Rare case with brief literature review. *Urol Case Rep.* 2017;13:92-93.
- [4] Somani K, Singh P, Verma S, Tandon T. An unusual case of xanthogranulomatous orchitis: A tumor mimic. *Apollo Med.* 2019;16(3):174-76.
- [5] Wiener LB, Riehl PA, Baum N. Xanthogranulomatous epididymitis: A case report. *J Urol.* 1987;138(3):621-22.
- [6] Usamentiaga E, Val-Bernal JF, Alonso-Bartolomé P, López-Rasines G, del Valle JI, Calabia A. Xanthogranulomatous orchitis. *Urology.* 1998;52(5):891-92.
- [7] Vaidyanathan S, Mansour P, Parsons KF, Singh G, Soni BM, Subramaniam R, et al. Xanthogranulomatous funiculitis and epididymo-orchitis in a tetraplegic patient. *Spinal Cord.* 2000;38(12):769-72.
- [8] Hajri M, Amna MB, Derouich A, Ayed M, Zermani F, Jilani SB. Orchites xanthogranulomateuses. A propos de sept cas [Xanthogranulomatous orchitis. Report of 7 cases]. *Ann Urol (Paris).* 2001;35(4):237-39. French.
- [9] Yap RL, Jang TL, Gupta R, Pins MR, Gonzalez CM. Xanthogranulomatous orchitis. *Urology.* 2004;63(1):176-77.
- [10] Demirci D, Ekmekçioglu O, Soyuer I, Emirdogan M. Xanthogranulomatous orchitis with scrotal fistulas. *Int J Urol.* 2004;11(8):686-88.
- [11] Salako AA, Olasode BJ, Eziyi AK, Osasan SA. Xanthogranulomatous orchitis in an adult Nigerian. *Int J Urol.* 2006;13(2):186-88.
- [12] Rifat Mannan AA, Kahvic M, Abu Sara Y, Bharati C. An unusual case of extensive xanthogranulomatous orchitis in a diabetic patient. *Med Princ Pract.* 2009;18(5):418-21.
- [13] Val-Bernal JF, González-Márquez P, Ramos-Barseló E, Portillo JA. Concurrent xanthogranulomatous orchiepididymitis and seminoma in the same testis. *Pathol Int.* 2010;60(1):55-58.
- [14] Repetto P, Bianchini MA, Ceccarelli PL, Roncati L, Durante V, Biondini D, et al. Bilateral xanthogranulomatous funiculitis and orchiepididymitis in a 13-year-old adolescent boy. *J Pediatr Surg.* 2012;47(10):33-35.
- [15] Ezer SS, Oguzkurt P, Temiz A, Bal N, Hicsonmez A. Xanthogranulomatous orchiepididymitis: A very uncommon cause of scrotal mass in childhood. *Urology.* 2013;82(1):228-30.
- [16] Yamashita S, Umemoto H, Kohjimoto Y, Hara I. Xanthogranulomatous orchitis after blunt testicular trauma mimicking a testicular tumor: A case report and comparison with published cases. *Urol J.* 2017;14(3):3094-96.
- [17] Hama Amin Said S, Abdalla RY, Aghaways I, Abdullah AM. Xanthogranulomatous orchitis: Review of the published work, and report of one case. *Urol Case Rep.* 2019;27:100908.
- [18] Sharma P, Ramteke P, Satapathy A, Ray M. Xanthogranulomatous orchitis presenting as a scrotal mass in an elderly male: Malignancy or mimicker? *Clin Med Insights Case Rep.* 2019;12:01-04.
- [19] Gongora E Silva RF, Pinto IC, Constantino ECN, Querichelli AFA, Spessoto LCF, Fácio FN Jr. Xanthogranulomatous orchitis: Case report of a rare condition. *AME Case Rep.* 2019;3:4.
- [20] Verma R, Dalal N, Yadav A, Pawar R, Singh S. Scrotal abscess with xanthogranulomatous epididymo-orchitis: A case report of rare diagnostic entity. *Trop J Pathol Microbiol.* 2020;6(7):443-45.
- [21] Murshed KA, Taha NM, Ben-Gashir M. A case of xanthogranulomatous orchitis and its preoperative diagnostic challenges. *Urol Case Rep.* 2020;32:101248.

PARTICULARS OF CONTRIBUTORS:

1. Assistant Professor, Department of Pathology, Government Institute of Medical Sciences, Greater Noida, Uttar Pradesh, India.
2. Professor, Department of Pathology, University College of Medical Sciences, Delhi, India.
3. Professor, Department of Pathology, University College of Medical Sciences, Delhi, India.
4. Senior Resident, Department of Pathology, University College of Medical Sciences, Delhi, India.
5. Senior Medical Officer, Department of Pathology, Oil and Natural Gas Corporation, Dehradun, Uttarakhand, India.

NAME, ADDRESS, E-MAIL ID OF THE CORRESPONDING AUTHOR:

Bhuvan Adhlakha,
Assistant Professor, Department of Pathology, Government Institute of Medical Sciences, Greater Noida-201310, Uttar Pradesh, India.
E-mail: bhuvanadhlakha@gmail.com

PLAGIARISM CHECKING METHODS: [Main et al.]

- Plagiarism X-checker: Jul 14, 2022
- Manual Googling: Aug 05, 2022
- iThenticate Software: Sep 22, 2022 (8%)

ETYMOLOGY: Author Origin

AUTHOR DECLARATION:

- Financial or Other Competing Interests: None
- Was informed consent obtained from the subjects involved in the study? Yes
- For any images presented appropriate consent has been obtained from the subjects. Yes

Date of Submission: **Jul 13, 2022**
Date of Peer Review: **Aug 08, 2022**
Date of Acceptance: **Aug 18, 2022**
Date of Publishing: **Jan 01, 2023**