

Detection of Coccidian Parasites using Auramine Rhodamine Stain: A Rapid and Sensitive Tool

DHARAVATH SAVITHA¹, A NEELIMA², KANNE PADMAJA³, UMABALA PAMIDI⁴, MADHUSUDHAN PATIL⁵, VIJAY DHARMA TEJA⁶



ABSTRACT

Introduction: Intestinal coccidian parasites known to cause opportunistic infections have increased since the past years and are often indistinguishable from other forms of community-acquired diarrhoea, which suggests a need for proper and rapid diagnostic techniques to recover and identify the organism.

Aim: To investigate if Auramine Rhodamine (AR) staining is a sensitive and time conserving staining technique in contrast to modified acid fast stain.

Materials and Methods: A descriptive observational study was conducted at Nizam's Institute of Medical Sciences, Hyderabad, India, over a period of three months (i.e., from July to September 2019). A total of 100 stool samples received by the Department

of Microbiology were subjected to macroscopic and microscopic examination by saline mount, iodine mount, kinyoun acid fast stain, modified AR staining.

Results: In the present study the prevalence of coccidian infections were observed to be 6%. Coccidian parasites reported were *Cryptosporidium* species and *Cystoisospora* species immunocompromised patients were found to be more prone to infections with coccidian parasites. The AR stain showed 100% agreement with modified acid fast stain.

Conclusion: This study concluded that the AR stain is a rapid and better stain than kinyoun acid-fast stain for the detection of coccidian parasites.

Keywords: *Cryptosporidium*, *Cystoisospora*, Immunosuppression, Microscopy

INTRODUCTION

An increase in the number of immunocompromised patients has led to an increase in the incidence of coccidian parasitic infections that often has a similar presentation as community-acquired diarrhoea presenting with severe infection in such patients which necessitates an early diagnosis and treatment for better prognosis [1]. Intestinal coccidian parasites include *Cryptosporidium parvum*, *Cystoisospora cayetanensis*, *Isospora belli* and *Sarcocystis* species causing significant gastrointestinal symptoms [1].

Cryptosporidium and *Cystoisospora* were assumed to be the causal agents of acute diarrhoea in animals, but in the recent years due to an increase in the number of immunocompromised patients these parasites have emerged as one of the leading causes of prolonged life threatening diarrhoea particularly in patients with Acquired Immunodeficiency Syndrome (AIDS) [2]. Coccidian parasites are intracellular cyst forming parasites, belonging to phylum apicomplexa of subkingdom protozoa which infects the intestinal epithelial cells predominantly. The most common mode of transmission is being the fecal-oral route via contaminated water or food. The pathophysiology of these parasites involves intestinal inflammation, villus blunting and malabsorption. Immunocompetent individuals remain asymptomatic or may present with mild to moderate self-limiting diarrhoea during the infective stage. Immunocompromised patients usually manifest as a severe form of disease with prolonged diarrhoea, extreme weight loss and generalised wasting [1].

Microscopic examination using Kinyoun acid fast stain is mostly used for detection of coccidian parasites which requires the use of oil immersion field for screening the smears which is time-consuming and cumbersome [3]. There are other detection methods like antigen assays, Immuno Fluorescence (IF), Polymerase Chain Reaction (PCR) which are more sensitive but as they are expensive they are not routinely used in all laboratories [4,5]. Most of the recommendations

in the work-up of community-acquired diarrhoea suggest only bacterial cultures [6]. There is every possibility of missing infections with coccidian parasites or delaying the diagnosis.

The AR stain has widely replaced the modified acid fast stain in mycobacteriology as it is easy and requires less time in screening the smears. However, this staining produces very characteristic images of coccidian oocysts and yields reliable and rapid results in comparison to modified acid fast stain [7].

This study was undertaken to investigate the application of a fluorescent stain i.e., AR staining as a sensitive and time conserving staining technique in rapid and easier identification of coccidian parasites compared to modified acid fast stain. With this study, we can recommend to routinely screen all the stool samples from immunosuppressed patients for coccidian parasites and help in the management.

MATERIALS AND METHODS

This was a descriptive observational study conducted at Nizam's Institute of Medical Sciences, Hyderabad, India, over a period of three months (i.e., from July to September 2019). As the study was only an observational study on stool samples, Ethical Committee clearance was not required and informed consent was not necessary. A total of 100 stool samples were included in the study.

Sample size calculation: Sample size was calculated using EPI software at approximately 5% prevalence, and 90% confidence interval [8].

Inclusion criteria: Freshly collected stool samples from patients having diarrhoea were included in the study.

Exclusion criteria: Leaked or stored samples, samples received in formalin, improperly collected specimens (e.g., rectal swabs), and specimens containing barium, oil, water, or urine were excluded from the study.

These samples were subjected to macroscopic examination and microscopy by wet mount, iodine mount, modified acid fast stain and AR staining.

Sample Collection

Faecal samples were collected in sterile disposable wide-mouth containers and were transported to the laboratory within three hours of collection. The faecal specimens were properly labelled with the patient name, hospital number, date and the time of collection. All the samples were subjected to macroscopic examination like colour, consistency and microscopic examination through saline and iodine mount.

Direct Wet Mount [9]

Saline and iodine mount: A drop of saline and Lugol's iodine was placed on left and right halves of the slide and small amount of faeces was mixed by a stick to form a uniform suspension and was examined under low power objective (10x) for detection of helminths eggs and larvae; followed by (40x) for protozoan cysts and trophozoites.

Modified Acid Fast Stain [9]

Kinyoun stain is the modified form of acid-fast stain and there is no need of heating in this staining procedure so, is also called cold method. A thin smear of faeces was made and fixed with methanol for one minute then the slide was flooded with carbol fuschin for five minutes and rinsed with 50% ethanol for 3-5 seconds and then rinsed with water, followed by decolourisation with 1% sulphuric acid for two minutes or until no colour runs from slide. Then the slide was rinsed with water and counter stained with methylene blue for one minute.

Interpretation: Acid fast oocyst of *Cryptosporidium* and *Cystoisospora* stain pink-red and background stain blue. Modified acid fast staining method was used as a reference method along with direct wet mount to compare the results of AR staining method.

Auramine-Rhodamine (AR) Stain [10]

It is a fluorescent stain with an advantage of using fluorochromes, AR which allows detection in a shorter time, compared to the regular acid fast staining for the observation of oocysts.

A thin smear was prepared and was heat fixed or methanol fixed for one minutes. The slide was allowed to cool and was flooded with AR stain for 15 minutes followed by a rinse with water and was flooded with 0.5% acid alcohol for two minutes and counter stained with potassium permanganate for two minutes. The slide was rinsed with water, air dried and screened under fluorescent microscope.

Interpretation: *Cryptosporidium* oocysts appeared as fluorescent yellowish green with a regular starry sky appearance and *Cystoisospora* oocysts fluoresce as bright reddish yellow against a dark background.

S. No.	Age (in years)	Sex	Ip/Op	Department	Diagnosis	Macroscopic	MAF	AR	Species
1	14	M	IP	MOG	Bone marrow transplant	Semi-solid	Pos	Pos	<i>Cryptosporidium</i>
2	53	M	OP	GM	HIV	Semi-solid	Pos	Pos	<i>Cryptosporidium</i>
3	22	F	IP	HEM	ALL	Semi-solid	Pos	Pos	<i>Cystoisospora</i>
4	22	F	OP	MGE	HIV	Semi-solid	Pos	Pos	<i>Cystoisospora</i>
5	45	M	OP	GM	Malignancy	Semi-solid	Pos	Pos	<i>Cystoisospora</i>
6	18	F	OP	KTU	Post renal transplant	Liquid	Pos	Pos	<i>Cryptosporidium</i>
7	45	F	IP	RH	SLE	Semi-solid	-	-	<i>Strongyloides larva</i>

[Table/Fig-2]: Clinical and demographic details of coccidian positive cases and *Strongyloides*.

MAF: Modified acid-fast stain; AR: Auramine rhodamine stain; MOG: Medical oncology; GM: General medicine; HEM: Haematology; MGE: Medical gastro enterology; KTU: Kidney transplant unit; HIV: Human immuno deficiency virus; ALL: Acute lymphoblastic leukemia; Pos: Positive; OP: Out patient; IP: In patient; M: Male; F: Female

STATISTICAL ANALYSIS

Data was analysed using Statistical Package for Social Sciences (SPSS) for Windows version 25.0.

RESULTS

A total of 100 stool samples were included in the study. The predominant age group was 31-40 years as shown in [Table/Fig-1]. A male preponderance was observed 77 (77%) while females were 33 (33%).

Age group	Number of cases (N=100)
0-10	0
11-20	14
21-30	15
31-40	29
41-50	23
51-60	10
61-70	7
71-80	2

[Table/Fig-1]: Age wise distribution of cases.

Out of 100 stool samples received, modified acid-fast stain detected coccidian parasites in six samples and the coccidian parasites reported were *Cryptosporidia* and *Cystoisospora*. This method was used as reference method. Commonest associated risk factor was immune suppression in all of the smear positive patients as shown in [Table/Fig-2]. Other parasites reported were *Strongyloides* larva seen in one sample [Table/Fig-3].

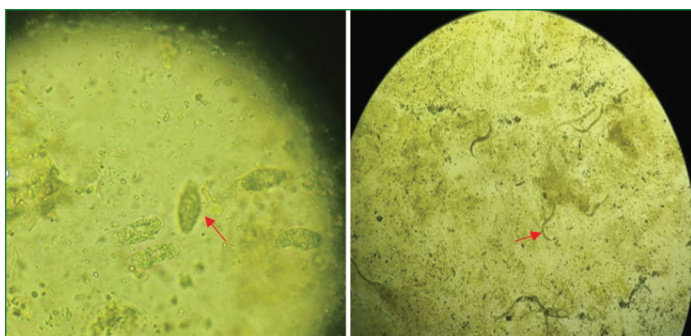
All the coccidian parasites reported by modified acid-fast stain from six samples were also detected by AR O stain which accounted for a 100% agreement of AR stain with modified acid fast stain.

Cryptosporidia oocyst: On modified acid-fast stain cryptosporidia spp oocysts were observed to be pink-red in colour with a diameter of 4-6 μ m and four sporozoites were appreciated internally. The background appeared uniformly blue as shown in [Table/Fig-4a].

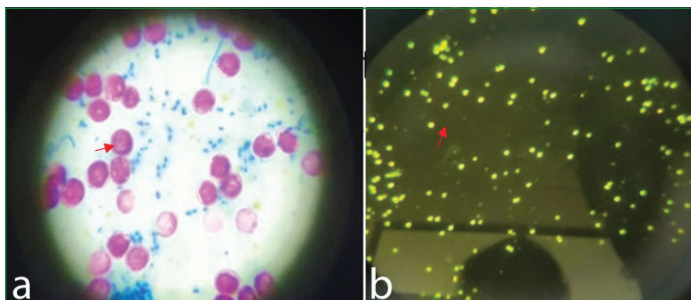
With AR stain, the *Cryptosporidium* spp cyst showed yellowish-green fluorescent cysts with a uniform size and morphology against a dark background [Table/Fig-4b].

Cystoisospora oocyst: On modified acid fast stain- the oocysts of isospora were observed to be ellipsoidal in shape around 23-33 \times 12-15 μ m in size with a pink stain. The sporoblast and oocyst (red arrow) wall were also stained. With AR stain they showed intense bright yellow fluorescence [Table/Fig-5]. These oocysts were also observed in direct wet mount.

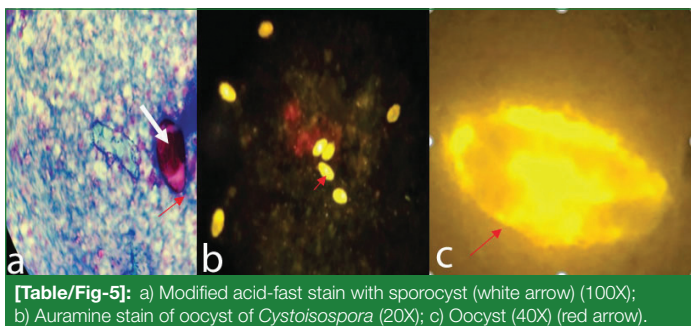
The preparation time of Kinyoun acid-fast stained smear in the laboratory was about 20 minutes with an additional five minutes for screening the slide. The AR staining preparation required 17 minutes, while screening of the smear required less than a minute per slide. *Cryptosporidium* was reported in three cases, *Cystoisospora* in three cases and *Strongyloides* in one case.



[Table/Fig-3]: Direct saline stool smear showing cyst of *Cryptosporidia* (Left) and larvae of *Strongyloides* (Right) (40X magnification).



[Table/Fig-4]: a) Modified acid fast stain (Left) (100X); and b) Auramine rhodamine stain (Right) of *Cryptosporidium* (20X).



[Table/Fig-5]: a) Modified acid-fast stain with sporocyst (white arrow) (100X); b) Auramine stain of oocyst of *Cryptosporidia* (20X); c) Oocyst (40X) (red arrow).

DISCUSSION

Intestinal coccidian parasites cause disease predominantly in immunocompromised patients, quite a few of them have been reported in patients with competent immune system also. These can be acquired easily and requires a prolonged duration of treatment [1]. There is battery of tests ranging from microscopy to molecular methods available for detecting these protozoa. But most of these are cumbersome, time consuming thus causing a delay in the diagnosis of such infections. Therefore, there is need for highly sensitive rapid techniques which aid in early diagnosis and accurate treatment [1].

Though, more sensitive methods like antigen detection, nucleic acid amplification assays are available but as they are expensive most of the laboratories still rely on microscopic examination [1].

Kinyoun acid-fast stain is used in detection and differentiation of coccidian parasites based on their size and morphology [1]. Auramine stain is a fluorescent dye used in mycobacteriology in detection of acid-fast microorganisms and has been found to be more sensitive than modified acid fast stain due to its ease of interpretation [1]. In India every Revised National Tuberculosis Control Programme (RNTCP) lab is provided with a Light Emitting Diode (LED) microscope which can be used simultaneously for screening of coccidian parasites without allocation of additional budget [11]. As plenty of smears are stained per day to screen for mycobacteria, additional staining of a few faecal smears attributes to very little additional technician time for the staining [12].

By both techniques, *Cryptosporidium* species (3%) and *Cystoisospora* species (3%) were the coccidian parasites detected. A similar finding was also observed by Abou El-Naga IF et al., 1998 and Hanscheid T

et al., [1,13]. This fluorescent stain was found to be a better stain as it could easily differentiate the artifacts from the coccidian parasites than Kinyoun acid-fast stain [1,13].

The ease of interpretation varied with two methods. The screening of Kinyoun acid-fast stained smears were tedious and required more time in interpretation due to examination of fields under oil immersion and misdiagnosis due to artifacts was also possible which are commonly seen in fecal samples. On the other hand, the AR stain for faecal samples similar to tubercle bacilli required a comparatively less time as it was extremely easy to visualise fluorescent organisms against a dark background at 100X magnification, with confirmation at 400X magnification. The morphological characterisation required 1000X magnification [1].

Herein, misdiagnosis would be minimised by simply detecting the artifacts based on their uneven morphology and homogenous staining. Kehl KS et al., in 1995, Ash LR and Orihel TC in 1997, Mansfield LS and Gajadhar AA in 2004 have reported that the fluorescent stain test was more accurate compared to Kinyoun's acid-fast stain test in resolving difficulties [14-16].

The reagent cost of the Kinyoun acid-fast stain was less than the AR stain. Also, the AR stain required a fluorescent microscope., Kehl KS et al., and MacPherson DW and McQueen R (1993) also observed that the cost of fluorescent staining and the availability of the fluorescent microscope are major obstacles to the use of the AR stain [14,17].

In the present study, AR staining had 100% agreement with modified acid fast stain, which was in agreement with earlier studies and may be attributed to the fact that it stains the outer wall of the oocyst as well as internal structures and the phenol present accelerates Auramine-Rhodamine stain penetration through oocyst walls [18]. *Cryptosporidium* oocysts fluoresce against a dark background and the smears can be easily examined under 20X or 40X objective [13,18,19]. Thus AR stain is better than modified acid-fast stain due to its lower screening time per smear (30 secs vs. 7 minutes) and feasibility of screening at low magnification (400X) [13]. So, it can be say that, both the staining techniques could identify the coccidian parasites in this study but AR can be preferred as it consumes less time and expertise.

Limitation(s)

Larger sample size would have shown more reliable results. Labs which do not have a fluorescence microscope would not be benefitted with this staining technique.

CONCLUSION(S)

The authors conclude that though modified acid fast staining technique is considered the gold standard for the detection of coccidian parasites, AR fluorescent stain should be considered as the screening technique of first choice due to its high sensitivity and ease of performance. However, in resource poor countries like India due to lack of availability of proper resources the detection of these parasites does not form a part of routine investigations and the probability of missing such infections are high, therefore health care providers should have a high suspicion for these infections especially in immunocompromised patients and should request testing for these parasites routinely. More studies are needed to develop such techniques which are less expensive, need no extra skills or expertise can be performed easily, give rapid results and can be easily available for clinical diagnosis.

REFERENCES

- [1] Abou El-Naga IF, Gaafar MR. Auramine-Phenol vs. Modified Kinyoun's Acid Fast Stains for Detection of Coccidia Parasites. *Lab Medicine*. 2014;45(1):65-73.
- [2] Nime FA, Burek JD, Page DL, Holscher MA, Yardley JH. Acute enterocolitis in a human being infected with the Protozoan *Cryptosporidium*. *Gastroenterology*. 1976;70(4):pp.592-98.

- [3] Gracia LS. Cumitech 30A. Selection and use of laboratory procedures for the diagnosis of parasitic infections of the gastrointestinal tract. Washington DC: American Society for Microbiology; 2003.
- [4] Garcia LS. Diagnostic medical parasitology. In: Truant AL, editor. Manual of commercial methods in clinical microbiology. Washington DC.: American Society for Microbiology; 2002. pp. 274-305.
- [5] Verweij JJ, Blange RA, Templeton K, Schinkel J, Brienen EA, van Rooyen MA, et al. Simultaneous detection of *Entamoeba histolytica*, *Giardia lamblia*, and *Cryptosporidium parvum* fecal samples by using multiplex real-time PCR. *J Clin Microbiol*. 2004;42(3):1220-22.
- [6] Guerrant RL, van Gilder T, Steiner TS, Thielman NM, Slutsker L, Tauxe RV, et al. Practice guidelines for the management of infectious diarrhea. *Clin Infect Dis*. 2001;32(3):331-51.
- [7] Baron EJ, Schenone C, Tanenbaum B. Comparison of three methods for detection of *Cryptosporidium* oocysts in a low prevalence population. *J Clin Microbiol*. 1989;27(1):223-24.
- [8] Ribes JA, Seabolt JP, Overman SB. Point prevalence of *Cryptosporidium*, *Cyclospora*, and *Isospora* infections in patients being evaluated for diarrhea. *Am J Clin Pathol*. 2004;122(1):28-32.
- [9] DPDx- Centers for disease control and prevention. Identification and diagnosis of parasites of public health concern. Available from: <http://www.dpd.cdc.gov/dpdx>.
- [10] Truant JP, Brett WA, Thomas W. Fluorescence microscopy of tubercle bacilli stained with auramine and rhodamine. *Henry Ford Hosp Med Bull*. 1962;10(2):287-96.
- [11] Reza LW, Satyanarayana S, Enarson DA, Kumar AMV, Sagili K, Kumar S, et al. LED-Fluorescence microscopy for diagnosis of pulmonary tuberculosis under programmatic conditions in India. *PLoS ONE*. 2013;8(10):e75566.
- [12] Henriksen SA, pohlenz JFI. Staining of cryptosporidia by a modified Ziehl-Neelsen technique. *Acta Veterinaria Scandinavica*. 1981;22(3-4):594-96.
- [13] Hanscheid T, Cristino JM, Salgado MJ. Screening of auramine-stained smears of all fecal samples is a rapid and inexpensive way to increase the detection of coccidial infections. *Int J Infect Dis*. 2008;12:47-50.
- [14] Kehl KS, Ciciello SH, Havens PI. Comparison of four different methods for detection of *Cryptosporidium* species. *Journal of Clinical Microbiology*. 1995;33(2):416-18.
- [15] Ash LR, Orihel TC. *Isospora belli* and *Sarcocystis* species. In: Atlas of Human Parasitology. 4th ed. Chicago, IL: ASCP Press; 1997:132-135.
- [16] Mansfield LS, Gajadhar AA. *Cyclospora cayentanensis*, a food- and waterborne coccidian parasite. *Vet Parasitol*. 2004;126(1-2):73-90.
- [17] MacPherson DW, McQueen R. Cryptosporidiosis: Multi attribute evaluation of six diagnostic methods. *J Clin Microbiol*. 1993;31(2):198-202
- [18] Smith H. Diagnostics. In: Fayer R, Xiao L, editors. *Cryptosporidium* and cryptosporidiosis. New York: CRC Press; 2008. pp. 173-208.
- [19] Kang G, Mathan MM. A comparison of five staining methods for detection of *Cryptosporidium* oocysts in fecal specimens from the field. *Indian J Med Res*. 1996;103:264-66.

PARTICULARS OF CONTRIBUTORS:

1. Postgraduate, Department of Microbiology, Nizam's Institute of Medical Sciences, Hyderabad, Telangana, India.
2. Associate Professor, Department of Microbiology, Nizam's Institute of Medical Sciences, Hyderabad, Telangana, India.
3. Associate Professor, Department of Microbiology, Nizam's Institute of Medical Sciences, Hyderabad, Telangana, India.
4. Additional Professor, Department of Microbiology, Nizam's Institute of Medical Sciences, Hyderabad, Telangana, India.
5. Additional Professor, Department of Microbiology, Nizam's Institute of Medical Sciences, Hyderabad, Telangana, India.
6. Professor and Head, Department of Microbiology, Nizam's Institute of Medical Sciences, Hyderabad, Telangana, India.

NAME, ADDRESS, E-MAIL ID OF THE CORRESPONDING AUTHOR:

Dr. A Neelima,
Associate Professor, Department of Microbiology, Nizam's Institute of Medical Sciences,
Punjagutta, Hyderabad-500082, Telangana, India.
E-mail: neelimasudhaharan@gmail.com

PLAGIARISM CHECKING METHODS: [Jain H et al.]

- Plagiarism X-checker: Jan 07, 2021
- Manual Googling: Dec 09, 2021
- iThenticate Software: Feb 26, 2022 (21%)

ETYMOLOGY: Author Origin

AUTHOR DECLARATION:

- Financial or Other Competing Interests: None
- Was Ethics Committee Approval obtained for this study? No
- Was informed consent obtained from the subjects involved in the study? No
- For any images presented appropriate consent has been obtained from the subjects. NA

Date of Submission: **Jan 06, 2021**Date of Peer Review: **Jan 16, 2021**Date of Acceptance: **Dec 26, 2021**Date of Publishing: **Apr 01, 2022**