

Breast Fine needle Aspiration Biopsy Cytology Reporting using International Academy of Cytology Yokohama System- Two Year Retrospective Study in Tertiary Care Centre in Southern India

POORNIMA V KAMATAR¹, VIDISHA S ATHANIKAR², US DINESH³

ABSTRACT

Introduction: The study is based on application of recently proposed International Academy of cytology (IAC) Yokohama system of Breast cytology.

Aim: The main objectives of the study were to categorise the Breast Fine Needle Aspiration Biopsy (FNAB) samples according to this new system of reporting and to assess the Risk of malignancy (ROM) for each category as well as the diagnostic yield of the Breast FNAB.

Materials and Methods: A Total of 470 FNAB cytology specimens from January 2017 to December 2018 were obtained. These were studied and reclassified according to newly proposed IAC Yokohama system of reporting. The ROM was determined. The sensitivity, specificity, Positive Predictive Value (PPV), Negative Predictive Value (NPV) and diagnostic yield of Breast FNAB were calculated accordingly.

Results: The Breast FNAB samples were distributed as follows: insufficient material 5%, benign 71%, Atypical probably benign 1%, suspicious for malignancy 2% and malignant 21%. Of the 470 cases, 179 cases had histopathological correlation. The respective ROM for each category was 0% for category 1 (insufficient), 4% for category 2 (benign), 66% for category 3 (atypical), 83% for category 4 (suspicious for malignancy) and 99% for category 5 (Malignant). The sensitivity, specificity, positive predictive value, negative predictive value and diagnostic accuracy were respectively 94.59%, 98.9%, 98.59, 95.74% and 96.97%.

Conclusion: Categorisation of the Breast FNAB cytology according to IAC Yokohama system of reporting helps pathologist in the diagnostic clarity and guides clinician in the appropriate patient management. IAC Yokohama system of reporting breast cytopathology serves as a common language to pathologist and clinician.

Keywords: Negative predictive value, Positive predictive value, Risk of malignancy

INTRODUCTION

Breast lumps are common in women of all ages. A thorough examination of breast is very important to rule out Breast cancer since it is the most common cancer in women. WHO estimates, more than half a million deaths worldwide are due to Breast cancer [1]. Recently, Breast cancer has overtaken cervical cancer in India with the incidence rate being 26 per 100,000 women population and mortality rate of 13 per 100,000 women population [2]. With the advent of triple testing for breast malignancies, FNAB has become an integral part of the evaluation of breast lesions. Triple testing includes breast clinical examination, mammography and/or ultrasonography, and cytology {FNAB/Core needle biopsy (CNB)} [3].

FNAB is a simple, relatively painless, inexpensive OPD procedure with speedy results. One of the major goals of Breast FNAB is to differentiate benign from malignant lesions. Differentiation is not possible in all cases due to significant overlap of the cytomorphologic features of both benign and malignant breast lesions [4]. To address these cytomorphologic grey zone uncertainties and to bring a degree of uniformity to the reporting system, in 1996 the National Cancer Institute (NCI) proposed five diagnostic categories [5]. Since then use of FNAC in the evaluation of breast lesions has changed substantially over the period of 20 years, mainly due to changes in screening programs and available treatments and recent preference for CNB.

In 2016, the International Academy of Cytology (IAC) established a "Breast Group" which included pathologists, radiologists, surgeons, and oncologists mainly to produce comprehensive and standardised guidelines for breast FNAB cytology reporting. The IAC Yokohama System for Reporting Breast Cytopathology incorporates the indications for breast FNAB cytology, FNAB technique, smear making and material handling, a reproducible standardised reporting system, the use of ancillary diagnostic and prognostic tests, and correlation with clinical work-up algorithms. Ultimately, this will facilitate clinician's understanding and use of FNAB cytology in breast pathology [6].

In the Yokohama System for Reporting Breast Cytopathology, the "Breast Group" has proposed a five-category classification: category 1- insufficient material; category 2- benign; category 3- atypical, probably benign; category 4- suspicious for malignancy, probably in situ or invasive carcinoma; and category 5- malignant [6]. In the present study, the newly proposed IAC Yokohama system of breast FNAB cytology was applied to breast FNAB cytology cases from the Pathology Department and ROM of each category and the diagnostic yield of this technique calculated. This categorisation of the Breast FNAB cytology according to IAC Yokohama system of reporting helps pathologist in the diagnostic clarity and guides clinician in the appropriate patient management, hence the need for this study. The main objectives of the study were to categorise the Breast FNAB samples according to this new system of reporting and to assess the ROM for each category as well as the diagnostic yield of the Breast FNAB.

MATERIALS AND METHODS

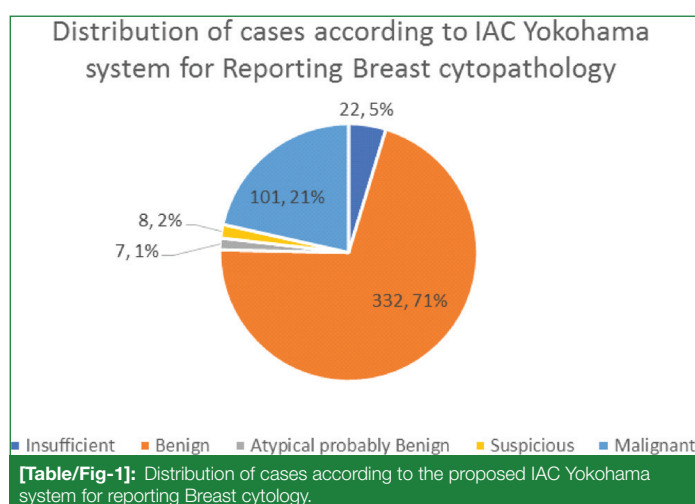
In the present retrospective study, a total of 470 FNAB cytology specimens from the Department of Pathology, SDM Medical College and Hospital, Dharwad were studied from January 2017 to December 2018. All the reported samples during the period were considered for the study. The relevant clinical and radiological details were collected from the hospital Laboratory information system. Later all FNAC's were retrospectively categorised using newly proposed IAC Yokohama Reporting system for Breast cytology by a single pathologist. Histologic samples were considered the gold standard and were available in 179 cases. The ROM was calculated for each category using the formula, number of confirmed malignant cases to the total number of cases in the diagnostic category [7].

STATISTICAL ANALYSIS

Statistical analysis was done using Microsoft Excel 2016. Standard descriptive analysis was performed. Sensitivity, specificity, PPV, NPV and diagnostic accuracy were calculated with the histologic diagnosis being the gold standard.

RESULTS

All the FNAB procedures were performed in the present study by experienced pathologists. The analysed cases were obtained between January 2017 and December 2018. Total of 470 cases were included in the study whose breast lump FNAB were carried out, of which 17 (4%) were male and 453 (96%) were female. All the FNAB breast cytology smears were retrospectively reviewed and categorised according to newly proposed IAC Yokohama system of reporting as insufficient material 5% (n=22), benign 71% (n=332), atypical probably benign 1% (n=7), suspicious for malignancy 2% (n=8) and malignant 21% (n=101) [Table/Fig-1]. The FNAB findings were correlated with histopathology [Table/Fig-2]. The respective ROM for each category was 0% for category 1 (insufficient), 4% for category 2 (benign), 66% for category 3 (atypical), 83% for category 4 (suspicious for malignancy) and 99% for category 5 (Malignant) [Table/Fig-3]. Sensitivity, specificity, positive predictive value, negative predictive value and diagnostic accuracy were respectively 94.59%, 98.9%, 98.59%, 95.74% and 96.97% [Table/Fig-4].



| Cytology cases | Benign histology | Malignant histology | Total |
|--------------------------|------------------|---------------------|-------|
| Insufficient | 2 | 0 | 2 |
| Benign | 90 | 4 | 94 |
| Atypical probably benign | 2 | 4 | 6 |
| Suspicious | 1 | 5 | 6 |
| Malignant | 1 | 70 | 71 |
| Total | 96 | 83 | 179 |

[Table/Fig-2]: Cytology and histopathology correlation.

| Categories | Risk of malignancy |
|--------------------------|--------------------|
| Insufficient | 0% |
| Benign | 4% |
| Atypical probably benign | 66% |
| Suspicious | 83% |
| Malignant | 99% |

[Table/Fig-3]: Risk of malignancy of the different diagnostic categories.

| Statistical parameters | Percentage (%) |
|---------------------------|----------------|
| Sensitivity | 94.59 |
| Specificity | 98.9 |
| Positive predictive value | 98.59 |
| Negative predictive value | 95.74 |
| Diagnostic accuracy | 96.97 |

[Table/Fig-4]: Sensitivity, specificity, PPV, NPV and diagnostic accuracy rate of breast cytology.

DISCUSSION

Breast lesions are not necessarily malignant and are mostly benign and there is a grey zone between the two. All the breast lesions should undergo triple assessment, which includes clinical, radiological and pathological examination to ensure correct diagnosis and precise treatment. Over the years, Ultrasound Guided FNAB cytology and CNB are used often in aiding the diagnosis. In Developing countries where financial constraints play a major role, FNAB still plays a pivotal role in diagnosis and management of breast lesions [4].

Standardised reporting system enables the reproducibility of the results across the institutions and countries and facilitates better communication between the pathologists and the treating surgeon. Uniform reporting system boosts the confidence of signing out pathologist especially with the grey zone lesions of breast FNAB cytology. This requires uniform system of reporting which is addressed by IAC Yokohama system of breast cytology [6].

The IAC Yokohama system classifies breast cytology smears into category 1-insufficient material; category 2-benign; category 3-atypical probably benign; category 4-suspicious for malignancy; and category 5-malignant [6]. The distribution of our samples according to IAC Yokohama system are comparable to studies by Montezuma D et al., and Wong S et al., [Table/Fig-5] [7,8]. In the present study, the percentage of atypical probably benign (category 3) is less compared to the Montezuma et al., study. According to our knowledge not many studies are there in the literature to compare with our study.

In the present study, correlation of FNAB cytology with gold standard histopathology was done and the risk of malignancy was calculated and later compared with the other studies [Table/Fig-6].

In the present study the sensitivity, specificity, positive predictive value, negative predictive value and diagnostic accuracy were respectively 94.59%, 98.9%, 98.59%, 95.74% and 96.97%. The results are comparable with Montezuma D et al., and Moschetta M et al., [7,9].

| Categories | Montezuma D et al., [7] | Wong S et al., [8] | Present study |
|--------------------------|-------------------------|--------------------|---------------|
| Insufficient | 209 (5.77%) | 301 (11%) | 22 (5%) |
| Benign | 2660 (73.38%) | 1937 (72%) | 332 (71%) |
| Atypical probably benign | 498 (13.74%) | 117 (4.3%) | 7 (1%) |
| Suspicious | 57 (1.57%) | 59 (2.2) | 8 (2%) |
| Malignant | 201 (5.54%) | 278 (10%) | 101 (21%) |
| Total | 3625 | 2696 | 470 |

[Table/Fig-5]: Comparison of distribution of samples according to IAC Yokohama system with other study.

| Categories | Montezuma D et al., [7] | Present study |
|--------------------------|-------------------------|---------------|
| Insufficient | 4.8% | 0% |
| Benign | 1.4% | 4% |
| Atypical probably benign | 13% | 66% |
| Suspicious | 97.1% | 83% |
| Malignant | 100% | 99% |

[Table/Fig-6]: Risk of malignancy was analysed and compared with the previous studies.

LIMITATION

Main limitations of our study are its small sample size and high risk of malignancy of the atypical category compared to previous studies. This could be attributed to the sampling error which can be overcome by Ultra sound guided FNAB and not all cases of atypical cases undergo biopsy confirmation. Authors observe that the same needs comparison with future articles with good sample size and large number of cohorts.

CONCLUSION

Categorisation of the Breast FNAB cytology according to IAC Yokohama system of reporting helps pathologist in the diagnostic clarity and guides clinician in the appropriate patient management.

FUTURE RECOMMENDATION

Authors would like to suggest incorporating this system routinely in cytopathology reporting for the better patient care and management.

REFERENCES

- [1] WHO | Breast cancer: prevention and control [Internet]. WHO. [cited 2019 Jul 14]. Available from: <http://www.who.int/cancer/detection/breastcancer/en/>
- [2] Gupta S. Breast cancer: Indian experience, data, and evidence. *South Asian J Cancer*. 2016;5(3):85.
- [3] Arul P, Masilamani S. Application of National Cancer Institute recommended terminology in breast cytology. *J Cancer Res Ther*. 2017;13(1):91.
- [4] Pandya AN, Shah NP. Breast fine needle aspiration cytology reporting: A study of application of probabilistic approach. *Indian Med Gaz*. 2013;6.
- [5] The Uniform Approach to Breast Fine Needle Aspiration Biopsy: A Synopsis. *Breast J*. 1996;2(6):357-63.
- [6] Field AS, Schmitt F, Vielh P. IAC Standardized reporting of breast fine-needle aspiration biopsy cytology. *Acta Cytol*. 2017;61(1):03-06.
- [7] Montezuma D, Malheiros D, Schmitt FC. Breast Fine needle aspiration biopsy cytology using the newly proposed IAC Yokohama system for reporting breast cytopathology: The experience of a single institution. *Acta Cytol*. 2019;63(Suppl.4):274-79.
- [8] Wong S, Rickard M, Earls P, Arnold L, Bako B, Field AS. The International Academy of Cytology Yokohama System for reporting breast fine needle aspiration biopsy cytopathology: A single institutional retrospective study of the application of the system categories and the impact of rapid onsite evaluation. *Acta Cytol*. 2019;63(Suppl.4):280-91.
- [9] Moschetta M. Comparison between fine needle aspiration cytology (FNAC) and core needle biopsy (CNB) in the diagnosis of breast lesions. *G Chir- J Surg* [Internet]. 2014 [cited 2019 Jul 17]; Available from: <http://www.giornalechirurgia.it/common/php/portiere.php?ID=73366646a0b094bb6a480507c74c39ea>

PARTICULARS OF CONTRIBUTORS:

1. Assistant Professor, Department of Pathology, SDM College of Medical Sciences and Hospital, Sattur, Dharwad, Karnataka, India.
2. Professor and Head, Department of Pathology, SDM College of Medical Sciences and Hospital, Sattur Dharwad, Karnataka, India.
3. Professor, Department of Pathology, SDM College of Medical Sciences and Hospital, Sattur Dharwad, Karnataka, India.

NAME, ADDRESS, E-MAIL ID OF THE CORRESPONDING AUTHOR:

Dr. Poornima V Kamatar,
S1, Gallery Apartment, I Cross, I stage, Shirur Park, Vidyanagar, Hubli-580021, Karnataka, India.
E-mail: drpookamatar_84@yahoo.co.in

FINANCIAL OR OTHER COMPETING INTERESTS: None.

Date of Submission: **Jul 15, 2019**
Date of Peer Review: **Jul 27, 2019**
Date of Acceptance: **Aug 03, 2019**
Date of Publishing: **Oct 01, 2019**