

# Testicular Germ Cell Tumours: A Review of Genetics, Morphology and Immunohistochemistry

KANWARDEEP KAUR TIWANA, SARITA NIBHORIA, ASHISH YADAV, TANVI MONGA, AKANKSHA BAJAJ

## ABSTRACT

Testicular Germ Cell Tumours (TGCTs) are rare tumours but they are the most common solid malignancy in young males and second leading cause of mortality. They exhibit biological diversity making them interesting for academics. They are true experiments of nature making their genetics very interesting. They provide an apt model to study transformation of pluripotent

cells from totipotent germ cell. The treatment modalities are different for TGCTs so pathologists must be very clear about the diagnosis, as the earlier correct diagnosis has high cure rate. This article reviews the genetics, histogenesis, morphological details of TGCTs with stress on use of immunohistochemical stains to differentiate tumours and various dilemmas faced by the pathologist.

**Keywords:** Genetics, Histogenesis, Testis

## INTRODUCTION

Testicular Germ Cell Tumours (TGCTs) are the most common solid malignancy in young men and second leading cause of mortality [1,2]. However, they comprise only 2% of human malignancies thus creating a lacunae in experience of pathologists, leading to various diagnostic challenges for the pathologists as their correct diagnosis has major therapeutic and prognostic implications. In this review we highlight the recent insights on genetics, therapeutic role of genetic mutations, pathogenesis and application of recent immunohistochemical markers in the differential diagnosis of TGCTs.

## Predisposing Factors

TGCTs account for 95% of all testicular malignancies and they show good therapeutic response if treated in early stages. They are broadly divided into two groups on the basis of their response to therapy as seminomas and Non-Seminomas (NSE), while the former is sensitive to both radiation and chemotherapy while later responds to chemotherapy only. Several risk factors have been identified which include cryptorchidism, spermatogenic and testicular dysgenesis, Klinefelter's syndrome, prior history of germ cell tumour and family history [3]. Overall a 6-10 fold increased risk has been estimated for first degree male relative of patient [4]. Approximately 2% of TGCTs have another affected family member with rare families having three or more affected individuals [4]. Thus indicating a recessive mode of inheritance.

## Histogenesis & Genetics

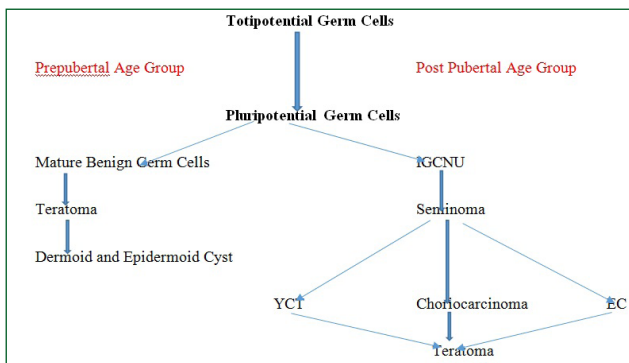
TGCTs are the true experiments of nature. They display

a spatially and temporarily abnormal manner patterns of differentiation that mimic stages normally undergone by developing zygote. They provide us a model to study the generation of a transformed pluripotent cell from totipotent germ cell. Earlier it was thought that this pluripotentiality manifests as histological differentiation into germ cell like undifferentiated (seminoma), primitive zygotic (epidermal cyst), embryonal somatically differentiated (teratoma), extra embryonic differentiated (choriocarcinoma, yolk sac tumour).

But according to Ulbright, histogenesis of teratomas is different [5]. They are divided into two categories prepubertal and post pubertal. In former they arise directly from pluripotential germ cell. This is similar to ovarian teratomas. However, in the case of post pubertal teratomas they are derived from malignant germ cell (IGCNU) that gives rise to non teratomatous forms of germ cell tumours which in turn differentiates to form teratomatous elements. This theory is supported by genetic analysis of teratomas and other TGCTs in post pubertal males [6]. Above model also explains one major issue i.e. association of pure teratomas in post pubertal males with IGCNU and metastases of non teratomatous types and uncommon occurrence of post pubertal testicular tumours without other germ cell tumour type [Table/Fig-1].

## Genetics

IGCNU is considered the precursor lesion for all adult TGCTs as explained by model of histogenesis. There are two models of origin of IGCNUs on the genetic basis. First model was proposed by Skakkebaek et al., in which he described the role of kit receptor/SCF paracrine loop (skp Cullen f-box) containing complex [7,8]. In this model they described that foetal germ cells which escaped normal development into



**[Table/Fig-1]:** Flow chart depicting histogenesis of TGCTs

spermatogonia, may undergo abnormal cell division mediated by kit/SCF paracrine loop leading to formation of ICGNU. This transformed germ cell been postulated to be susceptible to subsequent invasive growth through the mediation of post natal and prepubertal gonadotropin stimulation. This therapy is supported by expression of same immunophenotype markers by gonocytes and ICGNU cells.

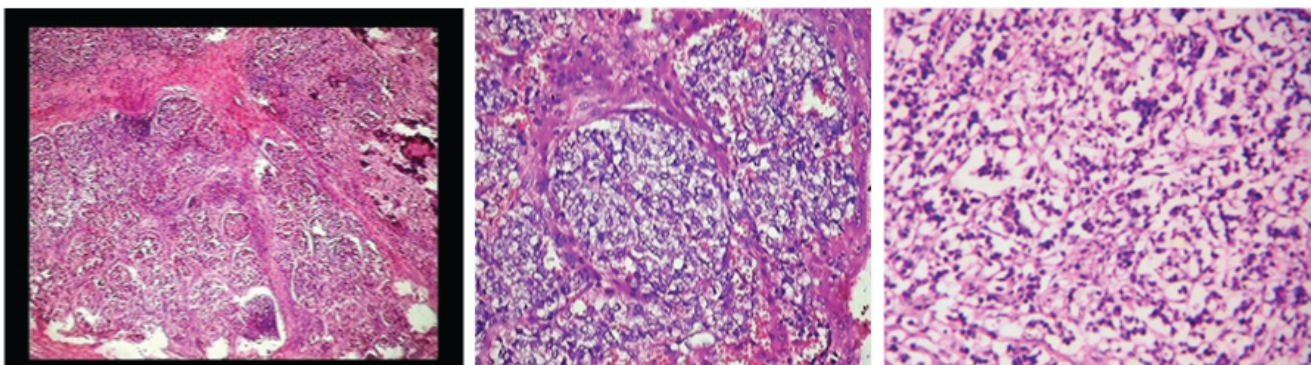
Second model was proposed by Chaganti and Houldsworth which stresses on four genetic properties of TGCTs [3,9] i.e. 1) increased 12p copy number 2) expression of cyclin D2 in ICGNU 3) consistent near triploid-tetraploid chromosome numbers. 4) abundant expression of wild p53. They postulated that most likely target cell for transformation during germ cell development may be one with replicated chromosomes that express wild type p53, harbours DNA breaks and prone to

apoptosis. Zygotene –pachytene spermatocyte represent such stage in which recombination checkpoints appear [10]. This is temporally longest phase during spermatogenesis with cell machinery stopping still to permit recombinational events to complete. The aberrant chromatid exchange events during this stage may lead to increase 12p copy number and overexpression of cyclin D2. Such a cell may escape the recombination checkpoints leading to genetic instability and reinitiation of cell cycle. Sicinski et al., concluded that cyclin D2 plays an important oncogenic role in TGCTs [11]. The germ cells that enter the cell cycle after cyclin D2 activation downstream events such as loss of tumour suppressor (RB1, DCC, NME) gene bringing genomic instability leading to neoplastic progression. Further studies show role of kit receptor and SCF. Kit receptor is expressed mainly by ICGNU and seminomas thus they are viewed in mitotically active transformed germ cells that have retained inhibitory mechanism [12]. On other hand NSEs (embryonal carcinoma, teratomas) appear to down regulate kit and up regulate SCF, thus consistent with loss of germ cell phenotype and acquisition of somatic fates [13].

Also due to deep understanding of genetics of TGCTs even cause of chemotherapy resistance has been identified i.e. subset that harbours Tp53 gene mutation [14]. The reason for this resistance is their inability to mount an apoptotic response after drug exposure because of an inactivity Tp53 gene mutation. Thus concluding that chemotherapy sensitive and resistance may be rooted in part in p53 dependent apoptotic pathway.

Tumours	IHC markers					
<b>ICGNU Vs. Atypical germ cells</b>						
	OCT 3/4	NANOG	PLAP	D2-40 podoplanin	SCF	
ICGNU	Positive	Positive	Positive	Positive	Positive	
Atypical germ cells	Negative	Negative	Negative	Negative	Negative	
<b>Seminoma Vs. YCT</b>						
	OCT 3/4	Cytokeratin AE1/AE3	AFP	Glypican-3		
Seminoma	Positive	Negative	Negative	Negative		
YCT	Negative	Positive	Positive	Positive		
<b>Seminoma Vs. EC</b>						
	Podoplanin	CD117	SOX117	Cytokeratin AE1/AE3	CD30	SOX2
Seminoma	Diffusely positive	Positive	Positive	Negative	Negative	Negative
EC	Negative	Negative	Negative	Diffusely positive	Positive	Positive
<b>Spermatocytic Seminoma Vs. Classical Seminoma</b>						
	OCT 3/4		PLAP			
Spermatocytic seminoma	Negative		Negative			
Classical Seminoma	Positive		Positive			
<b>Spermatocytic Seminoma Vs. EC</b>						
	CD30		Cytokeratin AE1/AE3			
Spermatocytic Seminoma	Negative		Negative			
EC	Positive		Positive			

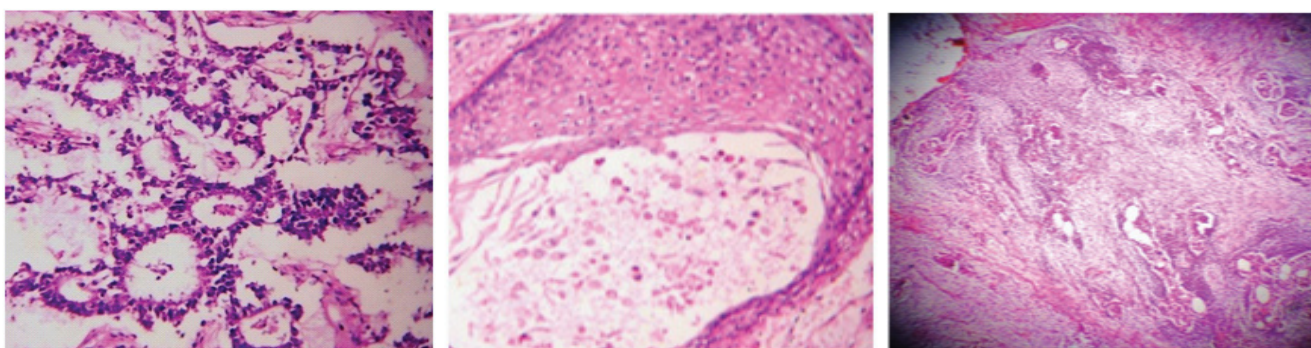
**[Table/Fig-2]:** IHC markers to differentiate various TGCTs



**[Table/Fig-3]:** Sections show classical seminoma exhibiting lobular arrangement with foci of dystrophic calcification (H&E X100)

**[Table/Fig-4]:** Sections show high power view of classical seminoma showing clear cells with well-defined borders and large nuclei (H&E X450)

**[Table/Fig-5]:** Sections show solid pattern in embryonal cell carcinoma (H&E X100). (Images from left to right)



**[Table/Fig-6]:** Sections show Yolk Sac Tumour exhibiting Schiller Duval Bodies (H&E X100)

**[Table/Fig-7]:** Sections show Epidermoid cyst (H&E X450)

**[Table/Fig-8]:** Sections show immature teratoma exhibiting blastemal component (H&EX100) (Images from left to right)

### Histological Types of Testicular Germ Cell Tumours (TGCTs)

In TGCTs seminoma is most common followed by Mixed germ cell tumours. Embryonal carcinoma, teratomas and yolk sac tumour as pure histological type are very low percentage more frequently they are seen as component of mixed germ cell tumours [Table/Fig-2].

### Intratubular Germ Cell Neoplasia Unclassified Type (IGCNU)

It is a precursor lesion and synonyms like Carcinoma In Situ (CIS) are used to describe this entity. As the name suggests they are seminiferous tubules but the malignant germ cells are large in size having abundant clear/vacuolated cytoplasm with large nuclei and prominent nucleoli. Nuclei is approximately 1.5 times larger than nuclei of background spermatogonia and have clumped chromatin with squared off flat edges. These are localised basally with absent spermatogenesis. They are present in seminiferous tubules adjacent to approximately 90% of TGCTs thus distinguishing them from many mimickers [15]. Differential diagnosis of IGCNU is with atypical germ cells as there is difference in magnitude of risk which is much less than that of IGCNU. Morphologically these cells are not basally located they have large nuclei, multinucleation, hyperchromasia with absence of nucleoli.

They may or may not be present in tubules with impaired spermatogenesis which is in contrast with IGCNU which occurs in tubules lacking spermatogenesis. On IHC markers OCT3/4, NANOG, placental alkaline phosphatase (PLAP), podoplanin (D2-40) and Stem Cell Factor (SCF) are positive for IGCNU but doesn't stain normal, hypertrophic or reactive spermatogonia. OCT3/4 (also known as POU5F1) is newly discovered nuclear transcription factor expressed in human embryonic stem cells. But major drawback of these markers is that they may be positive for germ cells in maturation delay. Thus pathologist need to be cautious while interpreting these markers. However Stoop H et al., highlighted that SCF can be used to differentiate between IGCNU and atypical germ cell [16]. But it needs to be authenticated by using various studies.

### Seminoma

It is the most common testicular germ cell tumour presenting as painless testicular mass with or without hydrocele. Grossly they appear as grey, cream, pale pink, soft homogeneous lobulated mass with areas of cystic degeneration and necrosis. Microscopically classical pattern is a sheet like arrangement of clear cells with well-defined cytoplasmic borders, large nuclei with prominent one or more nucleoli [Table/Fig-3&4]. They are separated by fibro vascular septae infiltrated by dense



mononuclear cell infiltrate. Granulomatous reaction and fibrosis is common and sometimes so extensive that they obscure the neoplasm. But seminomas show varied architecture thus making their diagnosis difficult. The histological differential is very important particularly for testicular tumours as yolk sac tumour and embryonal carcinoma is radio resistant.

## DIFFERENTIAL DIAGNOSIS

### Seminoma versus Yolk Sac Tumour

Architectural arrangement of seminomas is in form of tubules and microcystic pattern causes confusion with yolk sac tumour. Tubular arrangement in seminomas is basically pseudo glandular arrangement formed due to dyscohesion of tumour cells whereas YCT has true glands with well-defined lumens. Microcystic arrangement in seminomas is due to edema with tumour cells floating in it but in YCT they are found in firm myxoid stroma or vacuoles. Morphologically we need to focus on the cells despite of arrangement as seminoma cells are typical polygonal cells with clear cytoplasm round nuclei and prominent nucleoli in contrast cells of YCT are more pleomorphic. However in solid arrangement of YCT, the pathologists must look for other distinctive patterns in the same tumour [17]. Other points which help in differentiating YCT from seminoma is presence of IGCNU in adjacent tubules and inflammatory infiltrate and granulomas.

IHC is helpful as there is panel of four markers to differentiate above said tumours; cytokeratin (AE1/AE3), AFP ( $\alpha$  FP), glypican-3 and OCT3/4. First three markers are positive for YCT and OCT3/4 is positive in seminomas. Ye and Ulbright found that AFP was much less sensitive than glypican-3 in solid YCTs with both markers being 100% specific in differentiating from seminomas [1]. They also highlighted that despite improved sensitivity of glypican-3 over AFP for solid YCTs intensity of staining was less in comparison to other patterns [1].

### Seminoma versus Embryonal Carcinoma

These two tumours are closely related morphologically and immunophenotypically resembling embryonic germ cells thus they express same markers i.e. OCT3/4 and NANOG. But again differential is necessary as treatment modalities are different. Secondly the percentage of EC in mixed TGCTs is considered prognostic indicator and important consideration in deciding whether patients who have stage I are good candidates for management protocols [18,19,20]. Morphologically classical seminoma presents no diagnostic dilemma. Seminomas exhibiting atypical features like nuclear atypia, darker cytoplasm, increased cell crowding and those having pseudo glandular pattern create confusion and need to be differentiated from EC.

IHC is helpful in making differential between these tumours. Panel of markers are used cytokeratin (AE1/AE3), CD30, CD117 and podoplanin (D2-40). Cytokeratin (AE1/AE3) and CD30 are diffusely positive in EC and are negative (focally

positive) in seminomas whereas CD117 and podoplanin (D2-40) is positive in seminoma and negative (focally positive) in EC [21,22]. Recent markers SOX2 and SOX17 can be used but are not easily available. SOX2 shows nuclear positivity in EC whereas SOX17 shows nuclear positivity in seminomas [23,24].

### Seminoma with Syncytiotrophoblastic Cells

Various types of giant cells are seen in the seminomas and upto 7% of classical seminomas have recognisable tumour giant cells having morphological and ultra-structural features of syncytiotrophoblastic cells. But hcg positive cells are identified in upto 25% of seminomas [25,26]. The giant cells seen in seminoma are different from those seen in choriocarcinoma as they lack plexiform admixture of cytotrophoblast cells moreover hcg levels are markedly raised in choriocarcinoma. Seminomas with syncytiotrophoblastic cells have same prognosis as that of classical seminomas.

### Spermatocytic Seminoma

It is a tumour of older males with an average of 52 years, localised to testes unlike other GCTs which may be seen in the ovaries. It may be confused with seminoma as treatment for it is orchidectomy as it never metastasize. Morphologically they are more gelatinous than fleshy nature of seminomas. Microscopically tumours show sheeting arrangement with tumour cells varying in size from a lymphocyte to giant cell of above 100  $\mu$ m in diameter with bulk of intermediate cells. They lack IGCNU which is an additional point of differentiation. On IHC, it is negative for OCT3/4, PLAP (positive for seminomas) and negative for CD30 and cytokeratin AE1/AE3 (positive in EC).

### Embryonal Carcinoma

It is a tumor composed of undifferentiated primitive cells arranged in pattern varying from solid, syncytial and papillary [Table/Fig-5]. It is a tumor of young age with peak incidence of 30 years. It occurs as pure GCT in 2-10% cases while accounts for 80% of mixed germ cell tumors. Pathologist usually face only diagnostic dilemma while differentiating EC from atypical seminoma. IHC is helpful as CD30, EMA, and OCT 3/4 all are positive in EC.

### Yolk Sac Tumors

It is a type of TGCTs which is seen in pure form in infant and young children with peak age of 1.5 years and represents 70% of pediatrics GCT [27]. In adults it is seen as a part of mixed TGCT [27]. Morphologically YCT presents various histological patterns and several different patterns are seen admixed in the tumor [Table/Fig-6]. Telum was the first to describe these patterns i.e. microcystic, macrocystic, solid, glandular, papillary endothelial sinus, myxomatous, hepatoid, polyvesicular vitelline and enteric [28,29]. Differential from seminoma has already been discussed in great detail regarding morphological architecture and IHC.

Other patterns i.e. pure glandular and hepatoid pattern are rarely seen; but it is almost always seen in metastatic lesions resected after chemotherapy particularly after late recovery [30,31]. Most importantly in chemotherapy related changes which can confuse the pathologist is the presence of abundant basement membrane deposits surrounded by small groups of tumour cells. It may be confused as matrix producing mesenchymal lesion [32].

### Choriocarcinoma

Pure choriocarcinoma represents less than 1 % of TGCTs; and it as part of mixed GCT consisting 8% of TGCT's [33]. Morphologically the typical pattern of plexiform arrangement of syncytiotrophoblast cells with cytotrophoblast around foci of haemorrhage. The most common presentation is with metastasis. It is often disseminated prior to the discovery via hematogenous route as a consequence majority of the patients present with advanced stage disease. IHC marker i.e. hcg has a very high titer > 100,000 mIU/mL in circulation.

### Teratoma

Teratoma constitute about 4% of all TGCTs [33]. They occur as a component of mixed TGCTs and constitute as a component in 50% mixed TGCTs [33]. As explained by histogenesis model earlier prepubertal model are benign but their similar counterpart in post pubertal testis are malignant.

### Mature prepubertal teratoma

They represent 30% of TGCTs in children and are pure, lack cytological atypia, absence of IGCNN and are benign [34]. The germ cells of surrounding seminiferous tubules exhibit reactive changes.

### Dermoid & Epidermoid Cyst of Testes

Epidermoid cyst is relatively uncommon and dermoid cyst of testis is rare. There are two examples of post pubertal teratomas which are analogous to prepubertal teratomas. Dermoid cyst has presence of pilosebaceous units in the epidermal lining along with the presence of lipogranulomatous reaction which is characteristic and is due to leakage of oily sebaceous gland secretions from the cyst. Also other glandular elements, adipose tissue, cartilage and bone can also be seen. Epidermoid cyst is a simple cyst lined by squamous epithelium with no adnexal structure or other tissue types [Table/Fig-7]. Extreme care is needed while diagnosing the two entities. Presence of IGCNU excludes the diagnosis and indicates towards a teratoma.

### Mixed Germ Cell Tumours

This category includes germ cell tumour composed of two or more types. They consists 32-54% of GCTS. Age incidence depends on the presence or absence of seminoma. With seminoma the age is intermediate between that of seminoma and pure non seminoma; without seminoma the age is the same as pure non- seminoma. In testis pure germ cell tumor

type are infrequent but they are frequent in mixed form. Most commonly seen as embryonal carcinoma and teratoma each in 47% of cases followed by yolk sac in 41% [35]. 40% of MGCT contain varying number of syncytiotrophoblast cells [Table/Fig-8]. Polyembryona is a unique germ cell tumor listed by some under one histological type. However the individual component consisting of EC, YCT, etc. suggest MGCT.

### Burned Out GCT

TGCT exhibits spontaneous regression, with patient who presents with metastatic disease with a clinically in apparent primary but who has at least ghost burden of preexisting tumour on pathologic examination of testes. Microscopically the features helping in diagnosis are scar with calcification IGCNN, lymphoplasmacytic infiltrate, hemosiderin containing macrophages and testicular atrophy. The most common tumour exhibiting this phenomenon is choriocarcinoma but seminoma and EC also display this phenomenon.

### CONCLUSION

Testicular germ cell tumours are the rare tumours but they are the most common solid malignancy of young males. They show high cure rate if diagnosis is made correctly, so the pathologists must be very clear about their histopathological type. This article reviews the literature with stress on histogenesis, genetics and immunohistochemical markers of TGCTs and various dilemmas faced by pathologists.

### REFERENCES

- [1] Ye H, Ulbright TM. Difficult Differential Diagnosis in Testicular Pathology. *Arch Pathol Lab Med.* 2002; 136:435-466; doi: 10.5858/arpa.2011-0475-FA.
- [2] Jamal A, Tiwari RC, Murray T et al. Cancer Statics, 2004. *Ca Cancer J Clin.* 2004; 54(1):8-29.
- [3] United Kingdom Testicular Cancer Study Group. Aetiology of Testicular Cancer: association with congenital abnormalities, age of puberty, infertility and exercise. *Br. Med. J.* 1994; 308:1393-1399.
- [4] Chaganti RSK, Houldsworth J. Genetics and Biology of Adult Human Male Germ Cell Tumours. *Cancer Res.* 2000; 60:1475-82.
- [5] Ulbright TM. Germ Cell Tumours of the Gonads: a selective review emphasizing problems in differential diagnosis, rarely appreciated, and controversial issues. *Modern Pathology.* 2005;18:561-579, doi 10, 1038/Mod pathol. 3800310.
- [6] Kemek KM, Ulbright TM, Zhang S et al. Identical allelic loss in mature teratoma and different histologic component of malignant mixed germ cell tumours of testis. *Am J Pathol.* 2003; 163: 2477-84.
- [7] Skakkebaek NE, Rajpert de Meyts E, Jorgensen N, Carlsen E, Meidahl Peterson P, Gimercman A, Anderson A-G, Kold Jensen T, Andersen AM and Müller J. Germ cell cancer and disorders of spermatogenesis: an environmental connection? *Acta Pathol. Microbiol. Immunol. Scand.* 1998; 106:3-12.
- [8] Skakkebaek NE, Berthelsen JG, Gimercman A and Miller J. Carcinoma in situ of the testis: possible origin from gonocytes and precursors of all types of germ cell tumors except spermatocytoma. *Int J. Androl.* 1987; 10:19-28.
- [9] Chaganti RSK and Houldsworth J. The Cytogenetic theory of the pathogenesis of human adult male germ cell tumors. *Acta Pathol. Microbiol. Immunol. Scand.* 1998; 106:80-84.
- [10] Schwartz D, Goldfinger N, Kam Z and Rotter V. p53 controls low DNA damage – dependent premeiotic checkpoints and facilitates DNA repair during spermatogenesis. *Cell Growth Differ.* 1999; 10:665-75.
- [11] Sicinski P, Donaher JL, Geneg Y, Parker SB, Gardner H, Park MY, Robler RL, Richards JS, Mc Ginnis LK, Biggers JD, Eppig JJ, Bronson

- RT, Elledge SJ and Weinberg RA. Cyclin D2 is an FSH responsive gene involved in gonadal cell proliferation and oncogenesis. *Nature (Lond.)*. 1996; 384:470-74.
- [12] Shambloot MJ, Axelman J, Wang S, Bugg EM, Littlefield JW, Donovan PJ, Blumenthal PD, Higgins GR and Gearheart JD. Derivation of pluripotent stem cells from cultured human primordial germ cells. *Proc Natl Acad Sci USA*. 1998; 95:13726-31.
- [13] Rajpert-de Meyts SE, Skakkebaek NE. Expression of the c-KIT protein product in carcinoma in situ and invasive testicular germ cell tumor. *Int. J. Androl*. 1994; 17:85-92.
- [14] Houldsworth J, Xiao H, Murty VVVS, Chen W, Ray B, Reuter VE, Bost GJ, Chaganti RSK. Human male germ cell tumor resistance to cisplatin is limited to TP53 gene mutation. *Oncogene*. 1998; 16:2345-49.
- [15] Jacobsen GK, Henriksen OB, von der Maase H. Carcinoma in situ of testicular tissue adjacent to malignant germ cell tumors: a study of 105 cases. *Cancer*. 1981; 47(11):2660-62.
- [16] Stoop H, Honecker F, vande Gejm GJ et al. Stem cell factors as a novel diagnostic marker for early malignant germ cells. *J Pathol*. 2008; 216(1): 43-54.
- [17] Kao C-S, Idrees MT, Young RH, Ulbright TM. Solid pattern of testicular yolk sac tumors: a morphological and immunohistochemical study of 52 cases. *Mod Pathol*. 2011; 24(suppl 1):202A.
- [18] Wishnow KI, Johnson DE, Swanson DA, et al. Identifying patients with low risk clinical stage I non seminomatous testicular tumors who should be treated by surveillance. *Urology*. 1989; 34(6):339-43.
- [19] Moul JW, Mc Carthy WF, Fernandes EB, Sesterhenn EA et al. Percentage of Embryonal Carcinoma and of Vascular Invasion Predicts Pathological Stage in Clinical Stage I Non Seminomatous Testicular Cancer. *Cancer Res*. 1994; 54(2):362-64.
- [20] de Riese WT, de Riese C, Ulbright TM et al. Flow cytometric and quantitative histologic parameters as prognostic indicator for occult retroperitoneal disease in clinical stage I non- seminomatous testicular germ cell tumors. *Int J Cancer*. 1994; 57(5):628-33.
- [21] Nichans GA, Manwel JC, Copland GT, Scheitaur BW, Wick MR. Immunohistochemistry of germ cell and trophoblastic neoplasm. *Cancer*. 1988; 62(6):1113-23.
- [22] Idrees M, Saxena R, Cheng L, Ulbright TM, Badve S. Podoplanin, a novel marker for seminoma: a comparison study evaluating immunohistochemical expression of podoplanin and OCT3/4. *Ann Diagn Pathol*. 2010; 14(5):331-36.
- [23] de JJ, Stoop H, Gillis AJ et al. Differential expression of SOX17 and SOX 2 in germ cells and stem cells has biological and clinical implications. *J Pathol*. 2008;215(1):21-30.
- [24] Nonaka D. Differential expression of SOX 2 and SOX 17 in testicular germ cell tumors. *Am J Clin Pathol*. 2004; 28(9):1163-68.
- [25] Jacobsen GK, Von der Maase H, Specht L. Histopathological features of Stage I Seminoma treated with orchidectomy only. *J Urol Pathology* 1995; 3:85-94.
- [26] Mostofi FK, Sesterhenn IA. Pathology of germ cell tumors of testis. *Prog Clin Biol Res*. 1985; 203:1-34.
- [27] Grady RW, Ross JH, Kay R. Patterns of metastatic spread in prepubertal yolk sac tumor of testis. *J Urol*. 1995;153:1259-61.
- [28] Teillum G. Classification of endodermal sinus tumors (mesoblastoma vitellinum) and so called 'embryonal carcinoma' of the ovary. *Acta Pathology Microbiol Scand* 1965; 64:407-29.
- [29] Teillum G. Special tumors of Ovary and Testis and Related Extragenital Lesions. J.B.Lippincott: Philadelphia, 1976.
- [30] Michael H, Lucia J, Foster RS et al. The pathology of late recurrence of testicular germ cell tumors. *Am J Surg Pathol*. 2000; 24:257-73.
- [31] Niehans GA, Manivel JC, Lopland GT et al. Immunohistochemistry of germ cell and trophoblastic neoplasms. *Cancer*. 1988; 62:1113-23.
- [32] Damjanov I, Amenta PS, Zarghami F. Transformation of an AFP positive Yolk sac carcinoma into an AFP negative neoplasm: evidence for in vivo cloning of the human parietal yolk sac carcinoma. *Cancer*. 1984; 53:1902-07.
- [33] U Krag Jacobsen G, Barlebo H, Olsen J, Schultz HP, Starklint H, Sogaard H, Vaeth M. Testicular germ cell tumors in Denmark 1976-198. Pathology of 1058 consecutive cases. *Acta Radiol Oncol*. 1984; 23:239-47.
- [34] Grady RW, Ross JH, Kay R, Epidemiological features of testicular carcinomas in prepubertal population. *J Urol*. 1997; 158:1191-92.
- [35] Sesterhenn IA, Weiss RB, Mostofi FK, Stablein DM, Rowland RG, Falkson G, Rivkind SE, Vogelzang NJ. Prognosis and other clinical correlates of pathologic review in stage I and II testicular carcinoma: a report from the Testicular Cancer Intergroup Study. *J Clin Oncol*. 1992; 10:69-78.

**AUTHOR(S):**

1. Dr. Kanwardeep Kaur Tiwana
2. Dr. Sarita Nibhoria
3. Dr. Ashish Yadav
4. Dr. Tanvi Monga
5. Dr. Akanksha Bajaj

**PARTICULARS OF CONTRIBUTORS:**

1. Associate Professor, Department of Pathology, Guru Gobind Singh Medical College, Faridkot BFHUS Punjab, India.
2. Associate Professor, Department of Pathology, Guru Gobind Singh Medical College, Faridkot BFHUS Punjab, India.
3. Senior Resident, Department of Pathology, Guru Gobind Singh Medical College, Faridkot BFHUS Punjab, India.

4. Junior Resident, Department of Pathology, Guru Gobind Singh Medical College, Faridkot BFHUS Punjab, India.
5. Junior Resident, Department of Pathology, Guru Gobind Singh Medical College, Faridkot BFHUS Punjab, India.

**NAME, ADDRESS, E-MAIL ID OF THE CORRESPONDING AUTHOR:**

Dr. Kanwardeep Kaur Tiwana,  
H.No. 75 Medical College Campus Faridkot  
Punjab-151203, India.  
E-mail: kanwardeepjhajj@gmail.com

**FINANCIAL OR OTHER COMPETING INTERESTS:**

None.

Date of Publishing: Jul 01, 2015