

# A Morphologically Distinct Yet Seldom Seen Entity – Ovarian Collision Tumor

HEMALATHA.A.L , ASHOK. K. P, ANOOSHA. K, AMITA. K, RAGHUVVEER.C.R

## ABSTRACT

The co-existence of two adjacent and histologically distinct tumors in the same organ without histologic admixture at the interface are generically referred to as collision tumors. Although they have been reported in various organs, ovarian collision tumors are very rare. An ovarian teratoma with a cystadenoma or cystadenocarcinoma, typically of the mucinous type is the most commonly encountered combination. However, other histologic combinations are uncommon.

We report a rare case of a 60 years old female presenting with pain abdomen since four months, radiologically found to have a left cystic ovarian mass and diagnosed histologically as benign serous cystadenoma with a mature cystic teratoma embedded within its wall. We intend to highlight the possible co- existence of ovarian collision tumors even when the clinicoradiological findings are suggestive of single ovarian neoplasm. A possible misdiagnosis of malignancy can be avoided if careful examination is undertaken pre and post operatively and histologically.

**Keywords:** Mature teratoma, Ovarian collision tumor, Serous cystadenoma

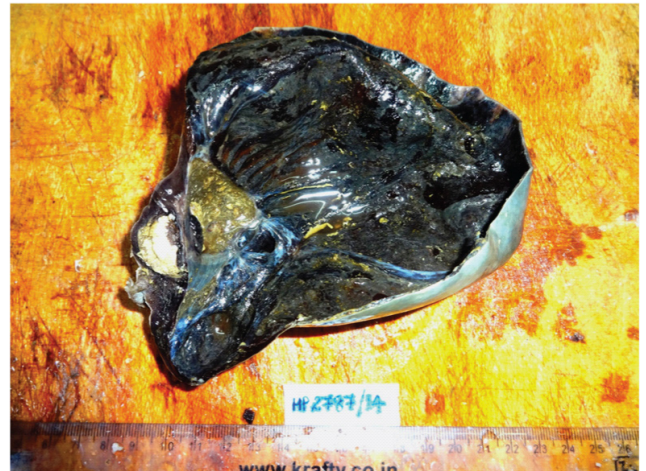
## CASE SUMMARY

A 60 years old female patient presented to the Department of Obstetrics and Gynaecology with complaints of pain abdomen of four months duration. Per-abdominal examination showed a mass corresponding to uterine size of 22 weeks which was firm in consistency with focal soft areas. Per-vaginal examination revealed a mass which was cystic to firm in consistency at the level of the posterior fornix. Ultrasonography revealed a unilocular cystic mass measuring 20 x 16 x 6 cms in size originating from the left ovary. The cyst wall was thick and the content lacked hyperechogenicity. A provisional clinico-radiological diagnosis of left ovarian tumor was formulated. Left oophorectomy was undertaken and the specimen submitted for histopathological examination.

## Histopathological findings

**Gross Examination** – A left cystic ovarian mass with a smooth surface measuring 19 x 16 x 6 cms with stretched overlying fallopian tube. Cut surface showed a unilocular cyst filled with brownish serous fluid and a thickened area in the cyst wall measuring 4 cm across. Cut surface of the thickened area showed pultaceous material admixed with hair. The other areas of the cyst wall appeared haemorrhagic [Table/Fig-1].

**Microscopy**– Sections studied from the main ovarian cystic mass showed a cyst wall made up of thickened fibrous tissue lined by ciliated low cuboidal epithelium [Table/Fig-2]. Sections from the focal thickened area in the wall of the ovarian cyst showed keratinized squamous epithelium, sebaceous lobules and hair follicles [Table/Fig-3]. The wall also showed stromal hemorrhage and congested blood vessels [Table/Fig-4].

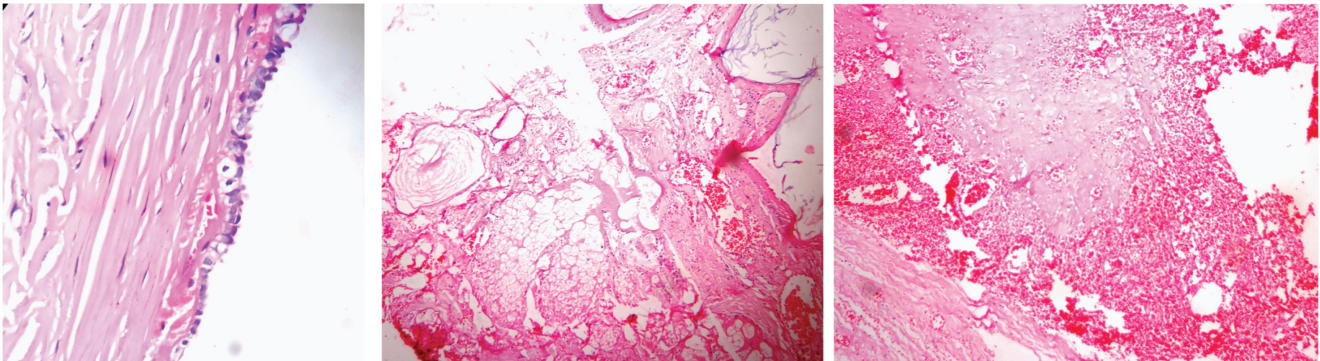


**[Table/Fig-1]:** Cut section of ovarian cystic mass showing uniloculated cyst with haemorrhagic cyst wall. Focal thickened area shows pultaceous area admixed with hair

**Final Diagnosis**– Benign serous cystadenoma with mature cystic teratoma embedded within the cyst wall associated with torsion.

## DISCUSSION

Co-existence of two contiguous but histologically distinct tumors in an organ with no histological admixture at the interface is referred to as “collision tumor”. The exact pathogenesis behind the occurrence of collision tumors is yet to be understood [1].



**[Table/Fig-2]:** Main cyst wall lined by ciliated low cuboidal epithelium with thickened fibrocollagenous wall in the serous cystadenoma component. (H & E, x 400)

**[Table/Fig-3]:** Section from focal thickened area in the main cyst wall showing keratinized squamous epithelium and pilosebaceous units in the mature cystic teratoma component, (H & E, x100)

**[Table/Fig-4]:** Large areas of stromal haemorrhage and congestion suggestive of torsion, (H & E, x 100)

Though the collision tumors have been reported in various other organs, ovarian collision tumors are rarely encountered and only a few cases have been described [2-4].

The most commonly reported combination in ovarian collision tumors is that of mature teratoma, a germ cell tumor of the ovary and mucinous tumors (cystadenomas/cystadenocarcinomas) which originate basically from the surface epithelium of the ovary.

Ovarian serous cystadenomas represent 20% of all ovarian tumors while ovarian mature cystic teratomas are the most common germ cell neoplasms representing 12-15% of ovarian neoplasms. While ovarian serous cystadenomas are unilocular cysts occurring in the elderly, mature cystic teratomas are usually bilateral [5].

The present case report along with a few earlier reported articles throws light on the possibility of co-existence of two histologically distinct ovarian neoplasms of different lineage in the form of a collision tumor which may lead to confusion and misdiagnosis if the knowledge regarding such an entity is lacking. Collision tumors are known to occur in every organ other than the ovaries as in the lungs, oesophagus, stomach, liver, kidneys, brain and bones. Ovarian collision tumors are indeed rare and only a few cases have been reported till date [5]. Various permutations and combinations of surface epithelial, germ cell and sex cord stromal tumors have been observed in ovarian collision tumors. But the most frequently reported combination is that of teratoma (a germ cell tumor) and cystadenoma or cystadenocarcinoma (a surface epithelial tumor) [5]. Majority of the reported cases had mucinous cystadenoma in combination with teratoma. But, serous cystadenoma coexisting with teratoma or in any other combination as in the present case is extremely rare. Extensive literature search revealed only two reported cases prior to the present case report [5,6].

Some cases of mature cystic teratoma presenting with Brenner tumor or fibrothecoma have also been reported [7] Another rare case of sertoli leydig cell tumor associated with

serous cystadenoma was reported by Seo et al., as early as in 1996 [8]. After this in 2013, a serous cystadenoma with co-existing stromal tumor having sex-cord stromal elements was reported by Bachhav [9].

Mature cystic teratomas are common in childhood, usually multiloculated with the content being greasy largely composed of sebum, keratin and hair [10]. In the present case, the greasy and pultaceous content with hair and cartilaginous material were incidentally detected on sectioning the thickened area of the cyst wall. The contrasting features were the elderly age of the patient and the uniloculation of the ovarian cyst. Serous tumors of the ovary constitute one fourth of all ovarian tumors and occur as uniloculated cysts in elderly females as in the present case [10].

## CONCLUSION

The present article along with the few earlier reported ones warrants a high degree of caution and suspicion for the clinician and the pathologist alike regarding the possibility of lesser known and rare entities like the ovarian collision tumors. A prompt recognition facilitates appropriate management of these tumors besides avoiding missing the hidden component or missing a possible malignancy in that component. Extensive tissue sampling especially in cystic ovarian tumors with focal thickening of the wall is recommended so as to unearth the buried component and diagnose collision tumor is such cases.

## CONSENT

Written informed consent was obtained from the patient for publication of this case report and accompanying images. A copy of the written consent is available for review by the Editor-in- Chief of this journal.

## REFERENCES

- [1] Bige O, Demir A, Koyuncuoglu M et al. Collision tumor: serous cystadenocarcinoma and dermoid cyst in the same ovary. *Arch Gynecol Obstet.* 2009;279: 767-70.

- [2] Allen C, Stephens M, Williams J. Combined high grade sarcoma and serous ovarian neoplasm. *J Clin Pathol*. 1992;45:263-65.
- [3] Scully RE, Mark EJ, McNeely WF, et al. Case records of the Massachusetts General Hospital. *N Engl J Med*. 1995;332:1631-47.
- [4] Nirenberg A, Ostor AG, Quinn MA. Collision tumour: serous adenocarcinoma and steroid cell tumour of the ovary. *Pathology*. 1992;24:60-62.
- [5] Papaziogas B, Souparis A, Grigoriou M, Tsiaousis P, Kogia E et al. A Rare Triple Coexistence of A Collision Tumor, A Benign Mature Cystic Teratoma And A Hemorrhagic Follicular Cyst Of The Ovaries. *The Internet Journal of Surgery*. 2007;14:57-60.
- [6] Choudhary S, Adishesha S. Collision tumors of ovary: A rare phenomenon. *Intl J of case reports and images*. 2012;3:68-70.
- [7] Moid F Y, Jones V. granulosa cell tumor and mucinous cystadenoma arising in mature cystic teratoma of the ovary: a unique case report and review of literature. *Annals of Diagnostic pathology*. 2004;8:96-101.
- [8] Seo E J, Kwon H J, Shim S I. Ovarian serous cystadenoma associated with sertoli leydig cell tumor - a case report. *Journal of Korean medical science*. 1996;11:84-87.
- [9] Bachhav A A. Serous cystadenoma with co-existing stromal tumor with sex-cord stromal elements: An extremely rare tumor. *Open Journal of Obstetrics and Gynecology*. 2014;4:105-108.
- [10] Juan Rosai. Rosai and Ackerman's Surgical Pathology - 10<sup>th</sup> Ed. Expert Consult: Elsevier. 1960-2112.

**AUTHOR(S):**

1. Dr. Hemalatha.A.L
2. Dr. Ashok. K. P
3. Dr. Anoosha. K
4. Dr. Amita. K
5. Dr. Raghuvveer.C.R

**PARTICULARS OF CONTRIBUTORS:**

1. Professor and HOD, Department of Pathology, No.12, Kalpatharu Bhavan, Adichunchanagiri Institute of Medical, Sciences, B.G.Nagara, Nagamangalataluk, Mandya District, Karnataka, India.
2. Post graduate, Department of Pathology, Adichunchanagiri Institute of Medical Sciences, B.G.Nagara, Nagamangalataluk, Mandya District, Karnataka, India.
3. Post graduate, Department of Pathology, Adichunchanagiri Institute of Medical Sciences, B.G.Nagara, Nagamangalataluk, Mandya District, Karnataka, India.

4. Associate Professor, Department of Pathology, Adichunchanagiri Institute of Medical Sciences, B.G.Nagara, Nagamangalataluk, Mandya District, Karnataka, India.
5. Post Graduate, Department of Pathology, Adichunchanagiri Institute of Medical Sciences, B.G.Nagara, Nagamangalataluk, Mandya District, Karnataka, India.

**NAME, ADDRESS, E-MAIL ID OF THE CORRESPONDING AUTHOR:**

Dr. Hemalatha. A.L  
 No: 156, 12<sup>th</sup> Cross, 2<sup>nd</sup> main, Jayanagar,  
 Mysore- 570014, India.  
 E-mail: halingappa@gmail.com

**FINANCIAL OR OTHER COMPETING INTERESTS:**

None.

Date of Publishing: Apr 01, 2015