

# Two Cases of Recurrent Hydatid Cyst in Liver at a Tertiary Care of Western Maharashtra, India

NIKUNJA KUMAR DAS<sup>1</sup>, SHAHZAD MIRZA<sup>2</sup>, RAJASHRI VILASRAO PATIL<sup>3</sup>, RABINDRANATH MISRA<sup>4</sup>, SAMEENA KHAN<sup>5</sup>

 CC BY-NC-ND

## ABSTRACT

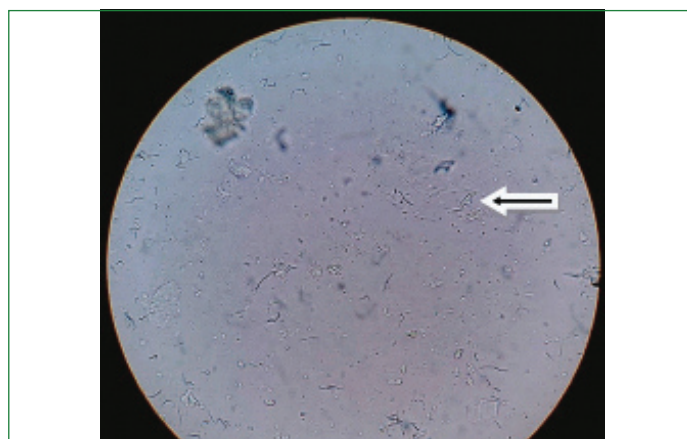
A hydatid cyst is a larval cyst in human tissues caused by a tape worm *Echinococcus granulosus*. It is a zoonotic disease. Cystic Echinococcosis (CE) is included in the list of Neglected Tropical Disease (NTD) by the World Health Organisation (WHO). Two such cases are presented. First, a 65-year-old man, admitted for cataract surgery gave a history of abnormal bowel habits from past one year. Puncture, Aspiration, Injection, Re-Aspiration (PAIR) procedure was performed and pigtail catheter was placed. Irrigation with hypertonic saline and betadine was performed followed by metronidazole and betadine for 12 days. Characteristic hooklet of *Echinococcus* spp. was seen and a definitive diagnosis of hydatid cyst was made. Second, a patient of 35-year-old female came to surgery outpatient department with the complaint of sudden onset of pain in right hypochondrium for 10 days over an operated scar. The patient was posted for PAIR and a pigtail catheterisation was done. Fluid was sent for microscopical examination, which showed protoscolices with internalised hooklets suggestive of Echinococcal infection. The hydatid cyst is a NTD. It is fairly common in agriculture based countries and may masquerade with a variety of symptoms or remain asymptomatic. Treatment can be difficult as well as challenging and can reoccur even after treatment and therefore patient should be followed up even after months of treatment.

**Keywords:** *Echinococcus granulosus*, Hooklet, Neglected tropical disease

## CASE REPORT

### Case-1

A 65-year-old man, admitted for cataract surgery, gave a history of abnormal bowel habits from past one year. He was advised USG abdomen and CT scan. After about 10 days he presented to surgery OPD with his reports. The person was a daily wage labourer by profession and a resident of Chinchwad in Pune. Patient and all of the family members were vegetarian and did not have history of pet and other significant contact with anyone. The CT scan revealed a cystic lesion in right lobe of liver of size 94×69×68 mm. His USG showed a heterogenous multiloculated, solid cystic lesion with peripherally arranged daughter cysts of size 92×73×78 mm in the right lobe of liver. Magnetic Resonance Cholangiopancreatography (MRCP) showed hydatid cyst of Rt. Lobe of liver in segment VI and VII, with multiple daughter cysts. Based on this a provisional diagnosis of hydatid cyst was made. A diagnostic laparoscopy was done under general anaesthesia. It revealed dense adhesions between omentum and parietal peritoneum and inferior border of liver. Hence an adhesiolysis was done. Next day a PAIR procedure was performed and pigtail catheter was placed. Irrigation with hypertonic saline and betadine was performed followed by metronidazole and betadine for 12 days. The fluid collected by PAIR was sent to Department of Microbiology for wet mount examination for hydatid sand. The sample was centrifuged and wet mount of sediment was seen under the microscope. Characteristic hooklet of *Echinococcus* spp. [Table/Fig-1] was seen and a definitive diagnosis of hydatid cyst was made. Follow-up USG was done after 12 days, which showed crushing and reduction of wall of hydatid cyst. The catheter was then removed and the patient was discharged. The patient was given a course of albendazole 400 mg twice a day for one month. On follow-up visit after about 3 months, the patient showed recurrence of hydatid cyst with daughter cysts by ultrasonography. The patient was not operated because of lack of symptoms and increased age, and was asked for follow-up again after three months for increase in size of the lesion. In view of non-increase in size, lack of symptoms and increased age the patient was under observation only.

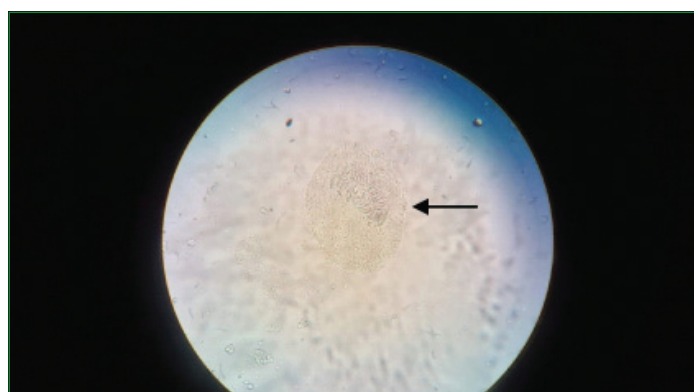


**[Table/Fig-1]:** Microscopic image of characteristic Hooklets in hydatid sand after centrifugation of the fluid.

### Case 2

A 35-year-old female patient came to surgery OPD with complaints of sudden onset of pain in right hypochondrium for 10 days duration over an operated scar. The patient was a known case of hydatid cyst for which she underwent exploratory laparotomy with excision and ectocyst drainage was done about six months back. The pain was sudden in onset, progressive, dragging, non-radiating with no aggravating or relieving factor. There was no history of diarrhoea, constipation, fever, nausea, vomiting, jaundice, melena, burning micturition, loss of appetite and weight loss. The patient was a resident of Malegaon, a farmer by occupation and had known history of exposure to stray dogs in the fields. The family history of exposure to dogs was present. However, the family history of similar illness was negative. The patient was afebrile, there was no icterus, pallor, lymphadenopathy, clubbing, oedema etc. Her vitals were stable. There was no organomegaly, palpable lumps and a healthy scar was seen. No other abnormality was seen in other organ system examinations. Routine haematological investigations were normal. Ultrasonography imaging of abdomen showed a 50×50 mm heterogeneous anechoic lesion in right lobe of liver

which was suggestive of residual hydatid cyst. CT scan also showed evidence of a recurring and residual cyst. The patient was posted for PAIR and a pigtail catheterisation was done. The fluid was sent for microscopic examination, which showed protoscolices with internalised hooklets suggestive of Echinococcal infection [Table/Fig-2]. The patient was managed with scolical agents. There was one occasion of an anaphylaxis reaction while attempting the aspiration of fluid, and was managed immediately with steroids.



**[Table/Fig-2]:** Characteristic protoscolices with rows of hooklets from a centrifuged fluid sample suggestive of *Echinococcus* spp.

Patient was discharged and a course of mebendazole (400 mg) for four weeks was advised. On contact telephonically, after about six months, the patient had a complaint of pain abdomen and was admitted to a local hospital. No other details could be gained as the patient was lost to follow-up. [Table/Fig-3] shows details of both the cases.

Features	Case 1	Case 2
Age	65 years	35 years
Sex	Male	Female
Presentation	Abnormal bowel habits	Acute pain abdomen
Dietary habit	Vegetarian	Non-vegetarian
Significant animal contact history	No	Yes
Site	Right lobe of liver	Right lobe of liver
Size	(94×69×68 mm)	(50×50 mm)
Operative procedure performed	PAIR	PAIR
Treatment	Albendazole 400 mg bd for a month	Mebendazole 400 mg for a month
Recurrence	Present	Present

**[Table/Fig-3]:** Comparison of two cases.

## DISCUSSION

The world celebrated the first ever “World neglected tropical disease day” on January 30, 2020. This is just to remind ourselves the very difficult task which we all have in hand towards the control and eradication of these diseases. There are at least 20 diseases which are included in this list. The important parasitic infections included in this list are Ascariasis, Hookworm disease, Trichuriasis, Strongyloidiasis, Echinococcosis, Filariasis, Schistosomiasis, Scabies, Leishmaniasis and Chagas disease. These diseases put an enormous amount of burden on public as are mostly chronic in nature; they promote poverty and can cause debilitating illness [1]. A hydatid cyst is a larval cyst in human tissues caused by the tape worm *Echinococcus granulosus*. It is a zoonotic disease and carnivores like dogs are the most common definitive hosts for this parasite. Herbivores like sheep and cattles act as the intermediate host. Humans are actually accidental hosts and get infection from food or water contaminated with dog faeces with ova of *E.granulosus* [2]. CE is included in the list of NTD by the WHO. NTD denotes a group of diseases which are common in tropical countries and had been neglected by researchers and

policy makers. These larval cestode diseases cause considerable morbidity, mortality along with socio-economic loss. In fact cysticercosis and CE have been termed as Neglected Zoonotic Diseases (NZD). This is a chronic disease and very indolent, hence may take many years to manifest, the reason why it's grossly under reported especially in areas where it's widely prevalent [3]. Clinical symptoms for hydatid cyst vary widely and it can range from being asymptomatic to manifest as an acute emergency. Hydatid cyst can be present in any part of the human body ranging from liver (most common), lungs, peritoneum, bones and brain. Small and intact cysts may not have any symptoms and are found incidentally whereas large and expanding ones may present as acute cases. The incidence of CE at this setting which is a tertiary care center in western Maharashtra is very minimal.

In India, it is more common in areas of sheep rearing like Jammu & Kashmir, Rajasthan, Andhra Pradesh [4]. The most common site for hydatid cyst is liver followed by lungs [5]. In this study, both the cases had cyst in liver, with no extra-hepatic locations. It is known to be a recurrent disease in spite of treatment. This study reports two such cases which were encountered in the year 2019. Both these cases turned out to be recurrent in nature. The first case was an incidental case though. The patient was admitted for a cataract surgery and also gave a history of bowel discomfort. But such complaint is not usually associated with hydatid cyst. Only on radiologic imaging and on microscopy, the patient was diagnosed to be a case of hydatid cyst. This patient did not have a close contact history with a dog, whereas the second case had a history of contact with stray dogs while working in the fields. Sarkar S et al., had 71% cases, which showed exposure to dogs [5]. The symptoms of hydatid cyst vary according to the site and size of the cyst. Rao SS et al., had lump in the abdomen as the most common (89.4%) presenting feature in their study [6]. Balik AA et al., had pain in abdomen as the most common presenting picture in their study [7]. In this study, one case was asymptomatic, whereas the other case presented with acute pain in abdomen.

Both the cases were treated with PAIR. Both the cases however turned out to be recurrent in nature after the treatment. Recurrences are very common in other cases of hydatid cyst also. Prousalidis J et al., had 27% of treated cases had recurrent cysts [8]. Diagnosing a hydatid cyst disease by radiologic imaging can be a challenging task, as it produces a myriad of pictures according to the location and the imaging technique is used [9]. So these two relatively rare and NTDs which were diagnosed in this setting had different presentations, both treated with surgical intervention and followed-up with antihelminthic drugs. But both of them turned out to be recurrent in nature. In both the cases, imaging studies were of immense help which was augmented by microbiological definitive diagnosis.

## CONCLUSION(S)

The hydatid cyst can be a fairly common in agriculture based country like India. It can present with a variety of symptoms or remain asymptomatic. Treatment and diagnosis is difficult as well as challenging. It can reoccur even after multipronged treatment so the patient may have to follow-up even after months of treatment. A strong index of suspicion should be there while dealing with space occupying lesions in the visceral organs both in clinics and laboratory, in a country like India, which is home to several of NTDs. An accurate diagnosis will go in a long way to manage these relatively uncommon diseases in a better way.

## Acknowledgement

We would like to thank the Department of General Surgery, Dr DY Patil Medical College and Hospital, Pimpri, Pune, Maharashtra, India for the samples, and providing with necessary information.

## REFERENCES

- [1] Hotez PJ, Aksoy S, Brindley PJ, Kamhawi S. World neglected tropical diseases day. *PLoS Negl Trop Dis*. 2020;14(1):e0007999.
- [2] Gautam S, Sharma A. Intracranial hydatid cyst: A report of three cases in North-West India. *J Pediatr Neurosci*. 2018;13(1):91-95.
- [3] Giri S, Parija SC. A review on diagnostic and preventive aspects of cystic echinococcosis and human cysticercosis. *Tropical Parasitology*. 2012;2(2):99-108.
- [4] Dayal R, Rathore SS, Verma D, Parmar S, Yadav RR, Gupta MK. The study of hydatid disease – A retrospective study of last 10 years in Western Rajasthan India. *IOSR Journal of Dental and Medical Sciences (IOSR-JDMS)*. 2016;15(2):45-47. e-ISSN: 2279-0853, p-ISSN: 2279-0861.
- [5] Sarkar S, Roy H, Saha P, Sengupta M, Sarder K, Sengupta M. Cystic echinococcosis: A neglected disease at usual and locations. *Trop Parasitol*. 2017;27:51-55.
- [6] Rao SS, Mehra B, Narang R. The spectrum of hydatid disease in rural central India: An 11- year experience. *Ann Trop Med Public Health*. 2012;5:225-30.
- [7] Balik AA, Basoglu M, Celebi F, Oren D, Polat KY, Atamanalp SS, et al. Surgical treatment of hydatid disease of the liver. *Arch Surgery*. 1999;134(2):166-69.
- [8] Prousalidis J, Kosmidis C, Anthimidis G, Kapoutzis K, Karamanlis E, Fachantidis E. Postoperative recurrence of cystic hydatidosis. *Can J Surg*. 2012;55(1):15-20.
- [9] Srinivas MR, Deepashri B, Lakshmeesha MT. Imaging spectrum of hydatid disease: Usual and unusual locations. *Pol J Radiol*. 2016;81:190-205.

### PARTICULARS OF CONTRIBUTORS:

1. Assistant Professor, Department of Microbiology, Dr D Y Patil Medical College, Hospital & Research Centre, Dr D Y Patil Vidyapeeth, Pimpri, Pune, Maharashtra, India.
2. Assistant Professor, Department of Microbiology, Dr D Y Patil Medical College, Hospital & Research Centre, Dr D Y Patil Vidyapeeth, Pimpri, Pune, Maharashtra, India.
3. Assistant Professor, Department of Microbiology, Dr D Y Patil Medical College, Hospital & Research Centre, Dr D Y Patil Vidyapeeth, Pimpri, Pune, Maharashtra, India.
4. Professor, Department of Microbiology, Dr D Y Patil Medical College, Hospital & Research Centre, Dr D Y Patil Vidyapeeth, Pimpri, Pune, Maharashtra, India.
5. Assistant Professor, Department of Microbiology, Dr D Y Patil Medical College, Hospital & Research Centre, Dr D Y Patil Vidyapeeth, Pimpri, Pune, Maharashtra, India.

### NAME, ADDRESS, E-MAIL ID OF THE CORRESPONDING AUTHOR:

Dr. Rajashri Vilasrao Patil,  
Flat No. 402, G Wing, Richwood Society, Sector 11, Spine Road, Pune,  
Maharashtra, India.  
E-mail: drpatilv22@gmail.com

### PLAGIARISM CHECKING METHODS: <sup>[Jain H et al.]</sup>

- Plagiarism X-checker: Jun 16, 2020
- Manual Googling: Aug 05, 2020
- iThenticate Software: Sep 22, 2020 (06%)

### ETYMOLOGY: Author Origin

### AUTHOR DECLARATION:

- Financial or Other Competing Interests: None
- Was informed consent obtained from the subjects involved in the study? No
- For any images presented appropriate consent has been obtained from the subjects. No

Date of Submission: **Jun 15, 2020**

Date of Peer Review: **Jul 20, 2020**

Date of Acceptance: **Aug 14, 2020**

Date of Publishing: **Oct 01, 2020**