

Prevalence and Clinicomycological Profile of Fungal Rhinosinusitis in a Tertiary Care Hospital

BICHITRANANDA SWAIN¹, SWATI JAIN², SUNITA KABI³

ABSTRACT

Introduction: Fungi are being increasingly implicated in the aetiopathology of Chronic Rhinosinusitis (CRS). Fungal Rhinosinusitis (FRS) is frequently seen in diabetic or immunocompromised patients, although it has also been reported in immunocompetent individuals. The spectrum of fungal involvement runs from benign colonisation to potentially life-threatening invasive disease. There are only a few landmark studies from India on FRS.

Aim: To determine the prevalence of FRS and to analyse its clinicomycological profile.

Materials and Methods: Thirty-nine patients with clinical suspicion of CRS during a period of one year were included in this prospective study. The sinonasal specimens were subjected to microscopy by potassium hydroxide (KOH) mount followed by

fungal culture as per standard mycological technique. Specimens were also subjected to Histopathological Examination (HPE). The obtained data from the study was analysed by chi-square test using Statistical Package for the Social Sciences (SPSS) software.

Results: The prevalence of FRS in this study was 41% (n=16) with a higher prevalence among third and fourth decades (n=10, 62.5%) of life, with a female predominance (n=11, 68.75%). *Aspergillus* spp. was the most prevalent organism (n=6) with *A. flavus* (4/6) being the commonest species. Allergic FRS (43.75%) was the most common presentation. The prevalence was higher among individuals who were immunocompetent (11/16).

Conclusion: As FRS varies in presentation, perfect mycological identification plays a crucial role in diagnosing chronic sinusitis and also provides therapeutic guidance for the treatment of infection with unusual agents.

Keywords: Allergic fungal rhinosinusitis, *Aspergillus flavus*, Chronic rhinosinusitis, Invasive fungal infections

INTRODUCTION

Rhinosinusitis (RS) is a common disorder of nose or sinuses affecting approximately 20% of the population [1]. It occurs in both acute and chronic forms with chronic form accounting for >90% of all cases of RS, has a slow protracted course and different aetiologies [2]. Fungi are uncommon causes of RS and were once thought to occur only in immunocompromised individuals. However, in recent years, its incidence has shown a marked increase in immunocompetent patients [3]. This may be due to a number of factors like increased awareness about fungal infections, improved diagnostic facilities of fungal culture and special staining techniques for pathological examination. FRS is classified into invasive and non-invasive types based on histopathological evidence of tissue invasion by fungi. The invasive forms include: acute invasive FRS, granulomatous invasive FRS and chronic invasive FRS. The non-invasive type includes: localised fungal infection of nasal and Paranasal Sinus (PNS) mucosa, fungal ball and fungus-related eosinophilic FRS that includes Allergic FRS (AFRS) [4]. Diagnosis is based on high index of clinical suspicion. Clinical presentation can provide clue to the diagnosis but the diagnosis depends upon direct microscopy, culture, histopathology of the tissue and radiology. Early diagnosis and accurate classification helps in deciding treatment protocol [5]. Despite awareness, it is always under diagnosed. Hence, this study was undertaken to determine the aetiological agents and prevalence of FRS and along with evaluation of treatment modalities.

MATERIALS AND METHODS

This prospective study was conducted over a period of one year (February 2018-January 2019) in the Department of Microbiology, IMS SUM Hospital, Bhubaneswar, Odisha, India. During this period 39 patients, with CRS admitted in the Department of Otorhinolaryngology were enrolled for this study after obtaining

informed consent from the patients. Institutional Ethical Committee approval was not required as there was no direct involvement of patient and mainly a laboratory work was done. Patients with chronic inflammatory disease of the sinuses undergoing Functional Endoscopic Sinus Surgery (FESS), chronic, recurrent or allergic sinusitis not responding to medical treatment were included in the study. All patients with acute sinusitis or malignancy of Paranasal sinuses (PNSes) were excluded from the study. The relevant clinical details of the patient including the co-morbidities and immune status were noted. CT scan of the PNSes was performed to look for bone erosion and heterogenous soft tissue opacity [6].

The exudates from paranasal mucosa, tissue biopsy from nasal polyp and tissue specimens were collected during FESS. Two portions of the specimen were sent in separate sterile screw capped containers, one with normal saline to the Mycology laboratory and another part with 10% formalin to histopathology lab. HPE of the samples was done using Haematoxylin and Eosin (H & E) and Periodic Acid-Schiff (PAS) stain [4]. The tissue samples received in the Mycology lab were minced into small pieces using sterile scalpel. A portion of the sample was subjected to initial screening by 10% KOH mount using light microscopy to look for the presence of fungal elements (hyaline or dematiaceous, septate or non-septate filamentous hyphae and budding yeast like cells). Rest of the sample was inoculated into two sets of Sabouraud's Dextrose Agar (SDA), in duplicates, one set with cycloheximide and gentamicin and other without cycloheximide. One set was incubated at 25°C and another at 37°C up to four weeks to see the visible growth. Further identification of the fungal isolates was done by macroscopic appearance of the colonies and microscopic morphology by Lactophenol Cotton Blue Mount (LPCB) and slide culture [4,6,7]. Results of fungal cultures were reviewed and correlated with clinical, histopathological and radiological findings which helped in arriving at final diagnosis and characterisation of FRS.

STATISTICAL ANALYSIS

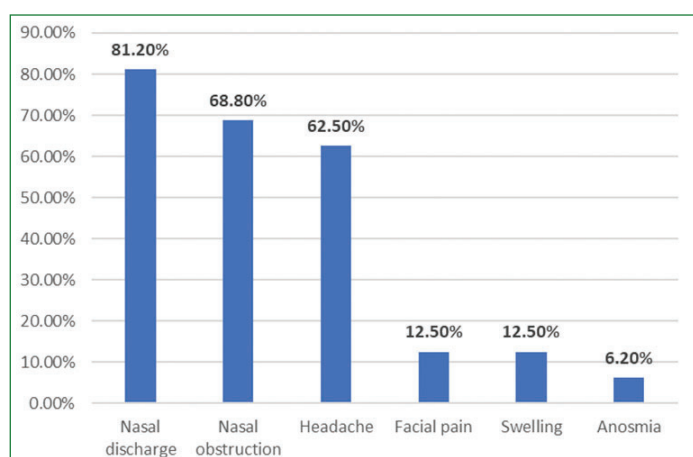
The data was analysed by chi-square test using SPSS software.

RESULTS

A total of 39 clinically diagnosed cases of CRS were included in this study. Of the 39 cases, 41% (n=16) of the patients had a fungal aetiology, with a highest prevalence in the third and fourth decades of life (n=10, 62.5%), with a female preponderance (n=11, 68.75%). Five of these 16 patients were immunocompromised as they were diabetics. No other associated co-morbidity was found [Table/Fig-1]. Of the all these FRS cases, 9 patients (56.2%) were from urban areas where as 7 patients (43.8%) were from rural areas. The chief complaints in these 16 cases included nasal discharge (13/16), nasal obstruction (11/16), headache (10/16), facial pain and swelling (2/16) and anosmia (1/16) [Table/Fig-2].

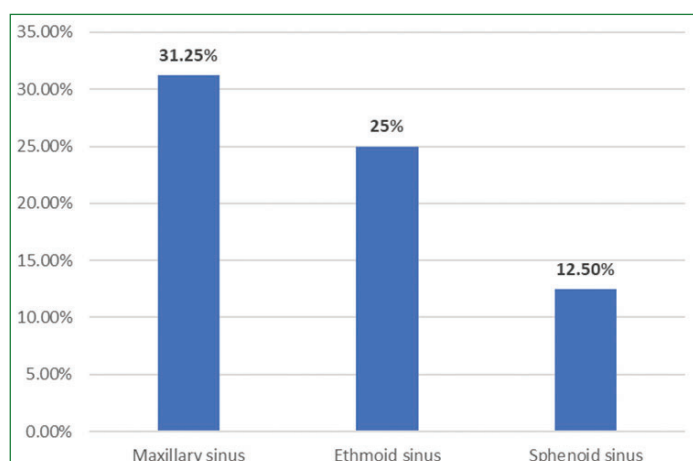
Age (years)	No. of patients with fungal rhinosinusitis	No. of males	No. of females	Immuno-compromised
11-30	2	0	2	0
31-50	10	4	6	3
51-70	4	1	3	2
Total	16	5	11	5

[Table/Fig-1]: Demography with immunity status among patients with fungal rhinosinusitis.



[Table/Fig-2]: Chief complaints and presenting symptoms in FRS cases.

Radiological evaluation revealed unilateral involvement of sinuses in 68.75% of patients (n=11) with involvement of maxillary sinus mostly (n=5), followed by ethmoid (n=4) and sphenoid sinuses (n=2) [Table/Fig-3]. PNS polyposis was seen in seven patients (43.75%) and one case of rhinosporidiosis was seen with features of irregular mass filling the left nasal cavity incompletely.



[Table/Fig-3]: Involvement of paranasal sinuses (PNS) in FRS cases

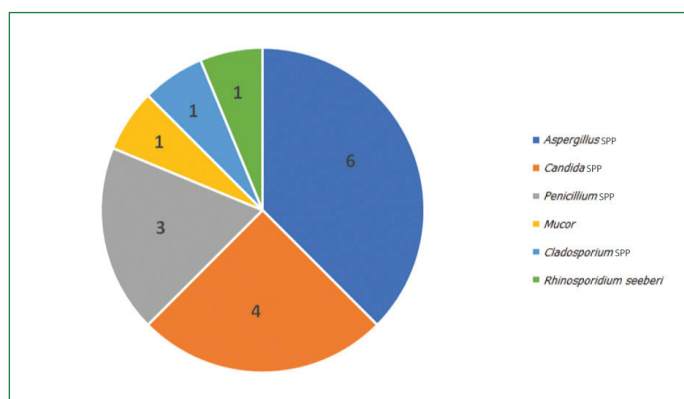
Fourteen of these 16 cases showed presence of fungal filaments on direct microscopy (KOH mount) and culture was positive for 15

cases [Table/Fig-4]. The difference between positive and negative KOH for the prediction of subsequent culture results was found significant at p-value <0.05.

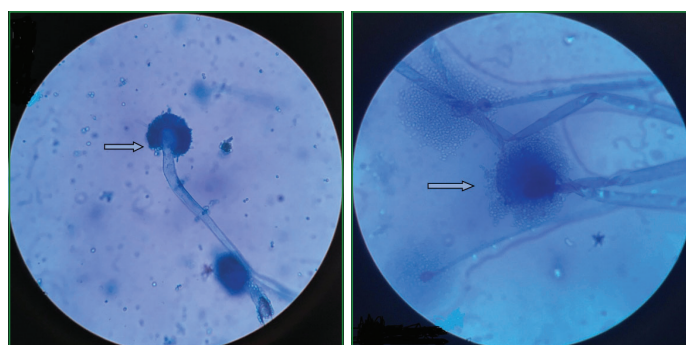
KOH	Culture Positive	Culture Negative	Total
Positive	13	1	14
Negative	2	23	25
Total	15	24	39

[Table/Fig-4]: Correlation of microscopy and culture method.

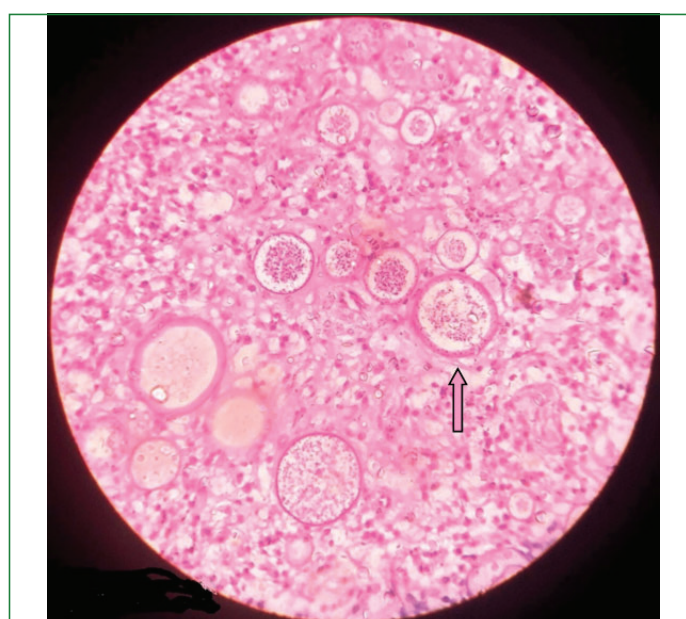
Aspergillus spp (n=6) was the most common organism isolated with *Aspergillus flavus* being the most common species (4/6) and the rest two species were of *Aspergillus fumigatus*; followed by *Candida* spp (n=4). Among *Candida* spp, two were *C. albicans* and rest two were *C. tropicalis* [Table/Fig-5-8].



[Table/Fig-5]: Distribution of isolated fungi from FRS cases.



[Table/Fig-6]: LPCB mount of *A. flavus* showing spherical vesicle with phialides covering the entire surface (40X); [Table/Fig-7]: LPCB mount of *Mucor* with columnella extending into sporangium containing sporangiospores (40X).



[Table/Fig-8]: H & E stained tissue section of nasal polyp showing thick walled sporangia containing endospores accompanied by inflammatory infiltrate (40X).

On the basis of HPE findings, seven cases were found to be of non-invasive FRS, eight were invasive FRS and one as rhinosporidiosis. All cases of non-invasive FRS included allergic FRS. Out of eight invasive FRS, three were Chronic Granulomatous invasive Fungal Rhinosinusitis (CGFS) and five were Chronic Invasive Fungal Rhinosinusitis (CIFS). Overall AFRS was the commonest variety [Table/Fig-9].

Isolates	HPE				Total
	AFRS	CGFS	CIFS	Rhinosporidiosis	
<i>Aspergillus flavus</i>	3	0	1	0	4
<i>Aspergillus fumigatus</i>	1	1	0	0	2
<i>Candida</i> spp.	1	1	2	0	4
<i>Penicillium</i> spp.	1	1	1	0	3
<i>Mucor</i> spp	0	0	1	0	1
<i>Cladosporium</i> spp	1	0	0	0	1
No growth	0	0	0	1	1

[Table/Fig-9]: Detailed breakup of fungal culture and Histopathological examination (HPE).

All the cases of non-invasive FRS were successfully treated by surgery without antifungals. During follow-up, all the cases recovered very well and there was no recurrence or death. All cases of invasive FRS underwent surgery along with empirical antifungals (parenteral voriconazole for *Aspergillus* infection, combination of systemic amphotericin-B and caspofungin for *Mucor* infection, oral itraconazole for *Candida* infection), recovered well without recurrence but one case left without taking treatment against medical advice.

DISCUSSION

More number of FRS cases are gradually detected worldwide. The prevalence is greater in tropical countries like India as fungi causing sinusitis are ubiquitous saprophytes that are continuously inhaled and deposited in the airway mucosa. CRS is characterised by sinonasal mucosal inflammation with a history of at least 12 weeks of persistent signs and symptoms despite medical therapy [8].

Prevalence rate of FRS varied and different workers had detected it as from 20 to 42.7% [2,6,7,9,10]. The current study had 16 cases (41%) of FRS among 39 suspected cases of CRS over a period of one year which was in concordance with studies by Das A et al., and Krishnan KU et al., [2,10] [Table/Fig-10].

Author	Year	Area	Incidence rate
Ravindra P and Viswanatha B [7]	2019	South India	20%
Prateek S et al., [9]	2013	Uttar Pradesh	21%
Suresh S et al., [6]	2016	South India	30%
Das A et al., [2]	2009	Chandigarh	42.7%
Krishnan KU et al., [10]	2015	South India	44.2%
Present study	2020	Odisha	41%

[Table/Fig-10]: Prevalence rate of FRS reported by various authors.

In a study by Samal P et al., most of FRS patients (63.4%) were males and 85% patients were in the age group of 21-30 years [11]. In another study, it was documented as FRS to be more commonly seen in the middle age group (30-50 years) with a male preponderance [2]. In this study highest prevalence of FRS was seen in third and fourth decades with a female preponderance. Similarly, a study by Michael RC et al., also reported FRS as more prevalent in the middle age group with a female predominance [12].

Nine patients were from urban areas and seven were from rural areas in the present study. Similar distribution of patients has also been suggested by Prateek S et al., [9]. Predominantly, urban affection is due to the fact that the population in these areas is more commonly exposed to the irritants, pollutants, dust,

factory residuals in comparison to those in the rural region. But Panda NK et al., found that majority of the patients were from a rural background [13]. A female patient who was diagnosed with rhinosporidiosis in this study belonged to rural area and had a history of regular bathing in a pond. Majority of the patients (11/16) with FRS in this study were immunocompetent and rest five were diabetics (immunocompromised) on medication. Similarly, Kandpal H et al., and Sigler L et al., had found FRS in immunocompetent and diabetics patients respectively [14,15]. Local factors such as recurrent sinusitis, increased exposure to air contaminated with mycotic spores are some of the factors responsible for fungal sinusitis in healthy individuals. The common presenting symptoms were nasal discharge, nasal obstruction, headache, facial pain and swelling, and anosmia which coincided with the study done by Ravindra P et al., [7]. In another study from Odisha, the common presenting symptoms were nasal obstruction (46%), nasal discharge (18%) and headache (16%) [11].

In this study, *Aspergillus* spp. was the most common organism isolated (6/16) with *A. flavus* being the commonest species, this finding that was supported by various studies across India [9,16]. On the basis of clinical, radiological, histopathological and mycological findings, out of 16 cases of FRS, seven were non-invasive FRS (AFRS) and eight were invasive FRS which was further subcategorised as granulomatous invasive FRS (3/8) and chronic invasive FRS (5/8). Most of the studies have reported AFRS to be the most common form of fungal rhino sinusitis [2,9,12,17] which was in concordance with this study. Maximum cases in the present study were having unilateral sinusitis and polyposis which is in concordance with a study by Melzer EO et al., who also reported nasal polyposis and pansinusitis as frequent presentation for AFRS patients. This may be the allergic response to the fungus colonising the mucin in their sinonasal cavities as patients with AFRS are commonly atopic [18]. FRS is a continuous spectrum of disease with considerable overlapping and transition from the non-invasive to acute invasive variety as proposed by various authors [2]. Therefore, continuous surveillance of prevalent sinonasal fungal infection and periodic monitoring of changing disease pattern of FRS patients are essential [10].

LIMITATION(S)

As the study had limited sample size, it would have been more informative with study of larger sample size.

CONCLUSION(S)

As FRS cases are gradually increasing and more number of these are reported from India, awareness is needed among the Microbiologists, Pathologists and treating physicians for proper diagnosis of FRS case. Mycological identification plays a crucial role in diagnosing chronic sinusitis and also provides therapeutic guidance for the treatment of infection with unusual agents.

REFERENCES

- [1] Schubert Ms. Allergic fungal sinusitis. *Otolaryngol Clin North Am.* 2004;37(2):301-26.
- [2] Das A, Bal A, Chakrabarti A, Panda NK, Joshi K. Spectrum of fungal rhinosinusitis; Histopathologist's perspective. *Histopathology.* 2009;54(7):854-59.
- [3] Chakrabarti A, Sharma SC. Paranasal sinus mycoses. *Indian J Chest Dis Allied Sci.* 2000;42(4):293-304.
- [4] Giri S, Kindo AJ, Rao S, Kumar AR. Unusual causes of fungal rhinosinusitis: A study from a tertiary care centre in South India. *Indian J Med Microbiol.* 2013;31(4):379-84.
- [5] deShazo RD, Chaplin K, Swain RE. Fungal sinusitis. *N Engl J Med.* 1997;337:254-59.
- [6] Suresh S, Arumugam D, Zacharias G, Palaninathan S, Vishwanathan R, Venkatraman V. Prevalence and clinical profile of fungal rhinosinusitis. *Allergy Rhinol.* 2016;7(2):e115-20.
- [7] Ravindra P, Viswanatha B. A clinicopathological and microbiological study of fungal rhinosinusitis. *J Otolaryngol ENT Res.* 2019;11(1):49-52.
- [8] Eloy P, Watelet JB, Rombaux P, Daele J, Bertrand B. Management of chronic rhinosinusitis without polyps in adults. *B-ENT.* 2005;Suppl1:65-74.

- [9] Prateek S, Banerjee G, Gupta P, Singh M, Goel MM, Verma V. Fungal rhinosinusitis: A prospective study in a University hospital of Uttar Pradesh. *Indian J Med Microbiol.* 2013;31(3):266-69.
- [10] Krishnan KU, Agatha D, Selvi R. Fungal rhinosinusitis: A clinicomycological perspective. *Indian J Med Microbiol.* 2015;33(1):120-24.
- [11] Samal S, Pradhan P, Rojita M. Correlation of clinical and hematological findings with the bony erosion in patients of allergic fungal sinusitis. *Otolaryngol Open Access J.* 2016;1(4):000123.
- [12] Michael RC, Michael JS, Ashbee RH, Mathews MS. Mycological profile of fungal sinusitis: An audit of specimens over a 7-year period in a tertiary care hospital in Tamil Nadu. *Indian J Pathol Microbiol.* 2008;51(4):493-96.
- [13] Panda NK, Sharma SC, Chakrabarti A, Mann SB. Paranasal sinus mycoses in North India. *Mycoses.* 1998;41(7-8):281-86.
- [14] Kandpal H, Aneesh MK, Seith A, Sharma S. Symptomatic perineural extension of fungal sinusitis in an immunocompetent person: imaging features. *Singapore Med J.* 2008;49(7):171-74.
- [15] Sigler L, Bartley JR, Parr DH, Morris AJ. Maxillary sinusitis caused by medusoid form of *Schizophyllum commune*. *J Clin Microbiol.* 1999;37(10):3395-98.
- [16] Chatterjee SS, Chakrabarti A. Epidemiology and medical mycology of fungal rhinosinusitis. *Otorhinolaryngol Clin Int J.* 2009;1(1):01-13.
- [17] Khattar VS, Hathiram BT. Allergic fungal rhinosinusitis. *Otorhinolaryngol Clin.* 2009;1(1):37-44.
- [18] Melzer EO, Hamilos DL, Hadley JA, Lanza DC, Marple BF, Nicklas RA, et al. Rhinosinusitis: Establishing definitions for clinical research and patient care. *J Allergy Clin Immunol.* 2004;114Suppl 6:155-212.

PARTICULARS OF CONTRIBUTORS:

1. Associate Professor, Department of Microbiology, SLN Medical College and Hospital, Koraput, Odisha, India.
2. Assistant Professor, Department of Microbiology, IMS and SUM Hospital, S^OA University, Bhubaneswar, Odisha, India.
3. Assistant Professor, Department of Microbiology, IMS and SUM Hospital, S^OA University, Bhubaneswar, Odisha, India.

NAME, ADDRESS, E-MAIL ID OF THE CORRESPONDING AUTHOR:

Dr. Swati Jain,
142, Doctors Enclave, Campus-3 IMS & SUM Hospital, Bhubaneswar, Odisha,
India
E-mail: drswati_jain@ymail.com

PLAGIARISM CHECKING METHODS: [Jain H et al.]

- Plagiarism X-checker: May 15, 2020
- Manual Googling: Jul 17, 2020
- iThenticate Software: Sep 15, 2020 (19%)

ETYMOLOGY: Author Origin**AUTHOR DECLARATION:**

- Financial or Other Competing Interests: None
- Was Ethics Committee Approval obtained for this study? No
- Was informed consent obtained from the subjects involved in the study? Yes
- For any images presented appropriate consent has been obtained from the subjects. No

Date of Submission: **May 14, 2020**Date of Peer Review: **Jun 19, 2020**Date of Acceptance: **Jul 29, 2020**Date of Publishing: **Oct 01, 2020**