

Role of Expression of p63 and Calponin in Prostatic Biopsies

S PREMALATHA¹, S SREELA², RAVI SIVARAMAN³

ABSTRACT

Introduction: Histopathological diagnosis of benign prostatic hyperplasia and prostatic carcinoma may pose problems due to presence of mimickers. p63 is confined to basal cells/myoepithelial cells of prostate and is absent in prostatic cancer. In prostate cancer there is presence of reactive stroma instead of normal fibro muscular stroma. Calponin is expressed in cytoplasm of smooth muscle cells of normal stroma and its decreased or loss of expression is believed to play a role in tumorigenesis.

Aim: This study is done to assess the expression of p63, a nuclear marker and calponin, a cytoplasmic marker in prostatic lesions and the relationship between the immunostaining and histologic grade of prostatic carcinoma.

Materials and Methods: Biopsy specimen from a total of 30 cases between ages 70-90 years which included 15 cases of Benign prostatic hyperplasia (BPH), 15 cases of prostatic carcinoma were obtained by Transurethral resection of prostate (TURP) and needle biopsies. For each case biochemical parameters were obtained. Immunohistochemical analysis

was performed on routinely processed, formalin fixed, paraffin embedded tissue. Tissue sections were cut at 5 µm thickness and mounted on gelatin coated slides. Immunohistochemical staining was done for both p63 and calponin. Expression of each of markers was graded accordingly.

Results: p63: Out of the 30 cases, 93% of BPH showed positive staining and 100% of prostatic carcinoma showed negative staining of which 8 cases showed cytoplasmic staining. Sensitivity was 93% and specificity was 100% respectively. Calponin: Out of the 30 cases, 100% BPH cases showed moderate to high staining index and 73% of prostatic carcinoma showed zero to low staining index. Sensitivity of calponin was 100% and specificity was 74%.

Conclusion: p63 and calponin are highly expressed in benign and pre neoplastic lesions. p63 is a valuable tool with high specificity in differentiating BPH from prostatic carcinoma. The decreased or absent stromal staining of calponin which indicates a reactive stroma in malignancy can be used in conjunction with p63 for confirmation of diagnosis of prostatic carcinoma.

Keywords: Benign prostatic hyperplasia, Basal cells, Prostatic cancer, Tumorigenesis

INTRODUCTION

BPH is an extremely common condition in elderly men. By the age of 60 years, 50% men have BPH which will increase to 90% by age of 90 years [1]. So it is considered as a normal part of ageing. Prostatic cancer is sixth most common cause of cancer in world and second most common cause of mortality being leaded by lung carcinoma [2].

Prostatic carcinoma diagnosis from biopsies can be difficult at times owing to small volume of biopsies, presence of mimickers like atypical adenomatous hyperplasia, atrophy [3]. Benign lesions retain basal layer of cells. Absence of basal layer provides supportive evidence of carcinoma [4,5]. In prostatic cancer the normal fibro muscular stroma is replaced by stroma composed of myofibroblasts and fibroblasts which is called as reactive stroma of wound repair type. This stroma promotes tumour progression by promoting angiogenesis, tumour cell proliferation and invasion [6,7,8].

p63/TP63 (Transformation related protein 63) is a nuclear transcription factor, homologue of p53 confined to basal cells of squamous epithelia, urothelium, breast, sweat glands, salivary glands and prostate and is required for growth, differentiation, apoptosis and senescence. P63 present in basal cells and absent in secretory and neuroendocrine cells in normal prostate. Infiltration of stroma indicates disruption of basal layer and will be negative in carcinoma. p63 as a basal marker can be useful in difficult situations to distinguish BPH from prostatic carcinoma [9,10,11].

Calponin is an actin filament associated regulatory cytoplasmic protein. It has three isoforms h1, h2, h3. h1 is basic isoform and is smooth muscle specific. h2 is neutral calponin found in smooth muscle cells and non-smooth muscle cells and h3 is acidic calponin [12]. It is smooth muscle marker and strongly expressed in normal

prostatic fibromuscular stroma. Decreased expression indicates destruction of smooth muscle like stroma due to stromal reaction/desmoplasia. This is called reactive stroma composed of fibroblasts, myofibroblasts, endothelial cells and immune cells. This will enhance tumor progression and metastasis. The calponin expression in prostatic carcinoma varies from nil to scanty due to replacement of fibromuscular stroma by reactive stroma.

Based on this concept the expression of p63, a diagnostic marker and h1 calponin on various pathological lesions of prostate in prostatic biopsies – both needle core biopsy and transurethral resection of prostate in patients between age group of 70-90 years is being analysed.

MATERIALS AND METHODS

The study was performed on 30 prostatic specimens in the department of pathology of Chengalpattu Medical College, Chengalpattu, Tamilnadu after getting clearance from institutional ethical committee. It was a retrospective observational study conducted during period of August 2015-August 2017 (24 months) in patients between age of 70-90 years. Tissue blocks of patients who were suspected/diagnosed as having benign hyperplasia and malignant prostatic lesions were taken. Patients with known prostatic carcinoma on therapy or those with metastasis were excluded. Clinical data and lab investigations including serum PSA level were taken.

Out of the 30 cases, 15 were Benign Prostatic Hyperplasia (cancer mimickers) and other 15 cases were of prostatic carcinoma of different Gleason grade [13]. Biopsies included those obtained from Transurethral resection of prostate (TURP-20 cases) and needle core biopsies (10 cases).

Formalin fixed paraffin embedded blocks were cut in to 5 µm thick sections and stained with Hematoxylin and Eosin stain. Slides were reviewed for lesions of BPH, prostatic carcinoma and presence and absence of PIN lesions. Prostatic carcinoma cases were graded according to Modified Gleason grading system 2014 [13,14,15].

Methods: IHC was performed in formalin fixed paraffin embedded tissues and two sections 5 µm were cut and mounted in gelatin coated slides. For p63 rabbit monoclonal antibody was used and for calponin h1 isotope monoclonal antibody was used.

The sections were deparaffinised, rehydrated and subjected to epitope retrieval in pressure cooker using TRIS-EDTA buffer. Slides were cooled for 15 minutes followed by endoperoxidase blocking using hydrogen peroxide. Primary antibody was added and incubated for 45 minutes followed by secondary antibody. After each step wash buffer was used. The end product was visualised using Diaminobenzidine and sections were counter stained using hematoxylin. Both positive and negative controls were incorporated. Positive control were sections from normal breast and negative control and negative control was same sections with addition of saline instead of primary antibody.

Evaluation of immunostaining: Result was taken as positive for p63 if the nucleus in basal layer stained brown with absence of stain on stroma and secretory epithelium. Sometimes patchy staining may be seen.

Calponin grading (h1-smooth muscle marker) [6] - percentage of positive staining cells and staining intensity were graded on a scale of 0-3: Staining percentage: 0=no staining, 1=1-33% positive cells, 2=34-66% positive cells, 3=67-100% positive cells. Staining intensity: 0=no staining, 1=staining obvious at x400, 2=staining at x100 but not x40, 3=staining obvious at x40. For each staining index = staining percentage x staining intensity. Staining index-0=zero, 1-2=low, 3-4=moderate and 6-9=high.

Sensitivity and specificity of markers calculated.

Statistics: The primary data was entered in MS Excel and analyzed using SPSS version 20.0. The results were presented in terms of tables and graphs. The descriptive statistics frequency and percentages were calculated.

The association between the categorical variables were analyzed by chi square test with 5% level of significance.

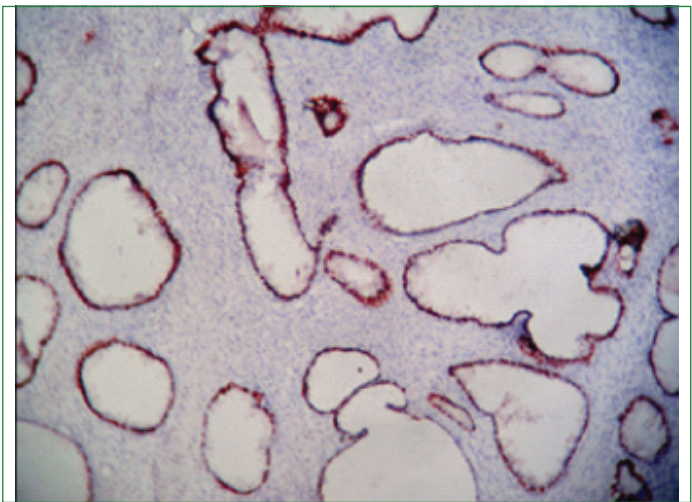
RESULTS

All cases were selected in age group of 70-90 years. Among BPH, majority of cases (75%) had serum PSA level between 10-20 ng/mL and among prostatic carcinoma majority of cases (94%) had serum PSA level >20 ng/mL.

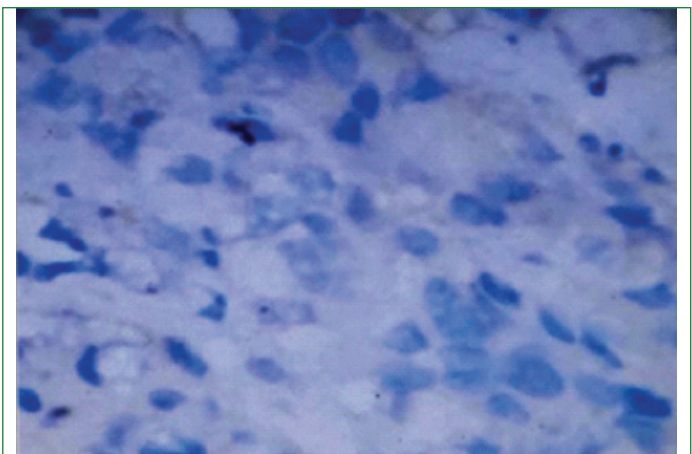
Among 15 cases of prostatic carcinoma studied, seven belong to Gleason score 3+3, four belonged to group 3+4, one in 4+3, one in 4+4 and two in 5+3.

Results of p63 staining: Out of 15 BPH cases, 93% [Table/Fig-1,2] showed positive staining. All prostatic carcinoma showed negative basal staining (100%) [Table/Fig-3] out of which 53% (8 cases) showed aberrant cytoplasmic staining (53%) [Table/Fig-4], p-value <0.01 and is statistically significant. Sensitivity of p63 was 93% and specificity was 100%. Results of Calponin staining.-Out of 15 cases of prostatic carcinoma 73% showed low staining index [Table/Fig-

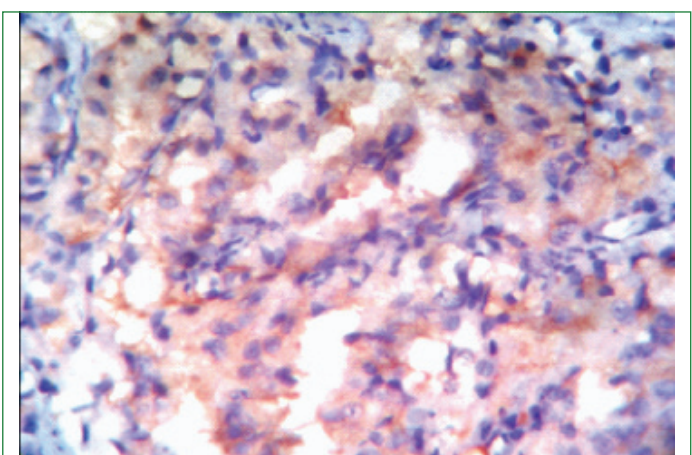
5,6], 37% moderate staining and none showed high staining index. Out of 15 cases of BPH 13 cases, 87% [Table/Fig-7] showed high staining index whereas only 13% showed moderate staining index [Table/Fig-8]. p value <0.01 and is statistically significant. Sensitivity was 100% and specificity was 74%. No comparison were done between 2 markers.



[Table/Fig-2]: p63-basal nuclear positivity (100x).



[Table/Fig-3]: p63-negative at 400x.



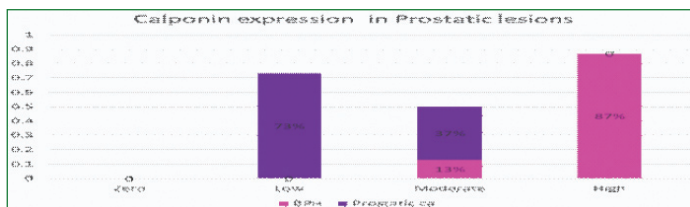
[Table/Fig-4]: p63- Cytoplasmic positivity (400x).

p63	BPH % (no of cases)	Prostatic carcinoma	Total
Positive	93% (14)	0	14
Negative	7% (1)	47% (7)	8
Cytoplasmic stain	0	53% (8)	8
Total	100% (15)	100% (15)	30
Chi sq=22.49			p<0.01

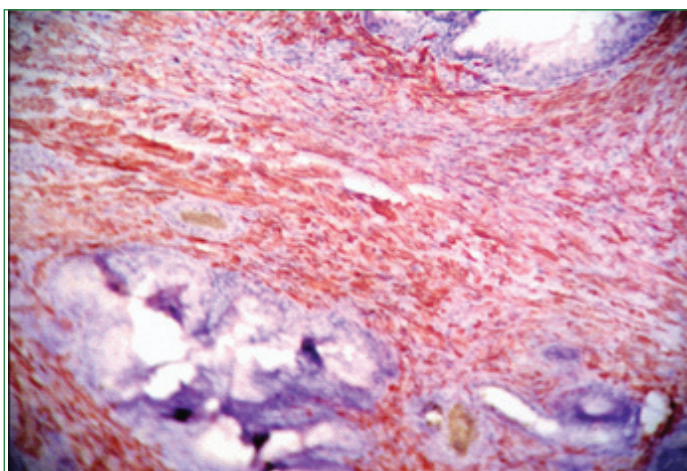
[Table/Fig-1]: Summary of results of p63 immunostaining in BPH and Prostatic carcinoma.

Calponin	BPH	Prostatic carcinoma	Total
Zero	0	0	0
Low	0	73% (11)	11
Moderate	13% (2)	37% (4)	6
High	87% (13)	0	13
Total	100% (15)	100% (15)	30
Chi sq=23.33			p<0.01

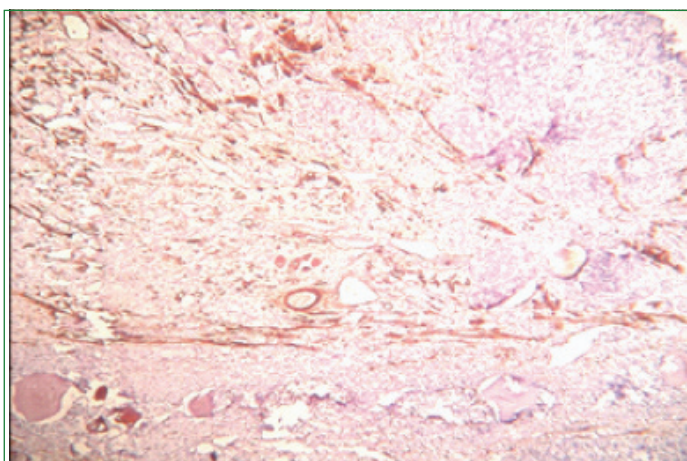
[Table/Fig-5]: Results of staining index for calponin in BPH and prostatic carcinoma.



[Table/Fig-6]: Calponin expression in benign and malignant lesions.



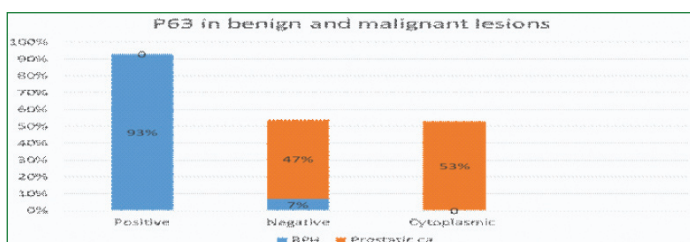
[Table/Fig-7]: Calponin- cytoplasmic of epithelium in carcinoma high staining index (100x).



[Table/Fig-8]: Calponin- Moderate index (100x).

DISCUSSION

Prostatic carcinoma is emerging as one of the leading cause of cancer in both developed and developing countries. Regarding age distribution a study done by Fahd et al., [1] shows majority cases in age group of 70-90 years. In the present pilot study only this age group was included. Basal cells are present in benign conditions of prostate and absent in malignant lesions. So p63 helps in distinguishing some ambiguous lesions from carcinoma. In the present study expression of p63 in benign and malignant lesions were studied [Table/Fig-9].



[Table/Fig-9]: p63 Expression in benign and malignant lesions.

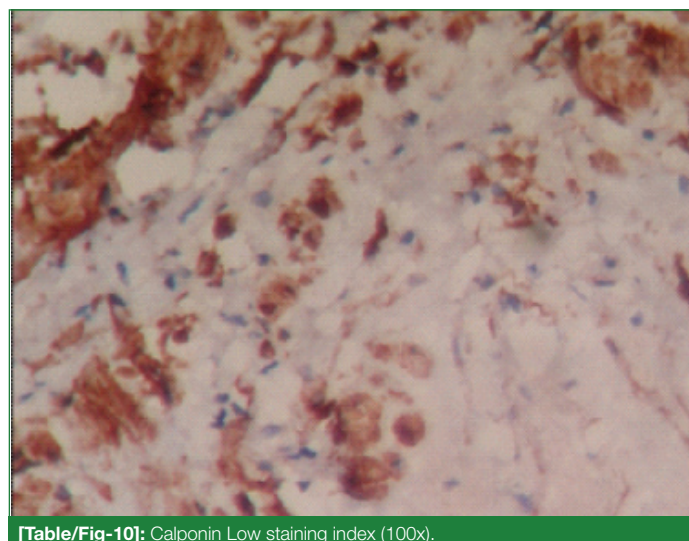
The present study coincides with Signoretti S et al., [10] which showed 100% positivity in BPH for p63 and 97% carcinoma were negative for p63. Shiran MS et al., [16] in a study of 72 biopsies involving 43

BPH and 29 prostatic carcinoma, 38 cases of BPH showed positive staining and all malignancy showed negative staining.

Study by leong et al., [17] showed that 128 out of 138 cases of BPH showed strong basal nuclear positivity and 106 out of 113 samples of carcinoma showed negative for p63. In study by Fahd et al., [1] 49 out of 50 BPH (98%) showed p63 positivity and 48 out of 50 (96%) carcinoma showed p63 negative staining.

Present study is in concordance with all these studies. Out of the 15 cases of BPH, 13 (93%) [Table/Fig-1] showed positive staining [Table/Fig-2] and one case showed negative staining. Among 15 cases of prostatic carcinoma none showed positive basal nuclear staining [Table/Fig-3]. Out of 15, eight cases (53%) [Table/Fig-1] showed cytoplasmic staining [Table/Fig-4]. All these were associated with high grade carcinomas. p63 positive prostatic carcinoma is rare. This is in concordance with Dhillon PK et al., [18] where he found correlation between aberrant cytoplasmic staining and number of cancer deaths in 298 cases of prostatic cancer. This cytoplasmic staining of p63 instead of usual nuclear pattern indicates an altered and potentially oncogenic function of the mislocalised protein in the tumour progression and survival. This cytoplasmic positivity is associated with higher tumour grade and increased mortality. In the present study we were not able to follow up patients to know the mortality or recurrence rate. Osunkoya A et al., [19] studied on 19 cases of p63 positive prostatic needle core carcinoma, these p63 showed cytoplasmic positivity of secretory cells. Morphologically, the acini in these p63-positive carcinomas frequently appear atrophic, with a high nucleo-cytoplasmic ratio, hyperchromatic nucleus and prominent nucleoli.

Main concept on calponin expression is formation of a reactive stroma in prostate cancer that will enhance tumour progression. The reactive stroma is composed of myofibroblasts rather than fibroblasts and smooth muscle cells in normal prostate. Chemical mediator TGF- β plays important role in converting fibroblasts to myofibroblasts. Calponin (h1) is a smooth muscle marker and will be expressed in normal and benign prostatic stroma and will be diminished or absent in prostatic carcinoma.



[Table/Fig-10]: Calponin Low staining index (100x).

In present study out of 15 BPH cases 13 (87%) showed [Table/Fig-5] strong staining index [Table/Fig-7] and two cases (13%) showed moderate staining index [Table/Fig-8]. In carcinoma 73% (11 cases) showed zero to low staining index [Table/Fig-10] and 4 cases showed moderate staining index [Table/Fig-5].

None showed high staining index. This is in concordance with study conducted by Jennifer A et al., [7] in which 96% of BPH showed high staining index and 78% of prostatic carcinoma showed low staining index [Table/Fig-11].

p63 expression	BPH		Prostatic Carcinoma		
	Positive	Negative	Positive	Basal negative	Cytoplasmic
Fahd et al.,	49 (98%)	1 (2%)	2 (4%)	48 (96%)	-
Shiran MS et al.,	38 (88%)	5 (12%)	0	29 (100%)	-
Leong et al.,	128 (93%)	10 (7%)	7 (6%)	106 (94%)	-
Dhillon PK et al.,	-	-	-	-	298
Present study	15 (100%)	0	0	15 (100%)	7(47%)
Calponin Staining index	BPH		Prostatic Carcinoma		
	O/Low - Moderate - High		O/Low - Moderate - High		
Jennifer A et al.,	-	96%		78%	-
Present study	-	13%	87%	73%	27%

[Table/Fig-11]: Comparison with other studies.

LIMITATION

The relation between aberrant cytoplasmic staining of p63 and with increased mortality in literature could not studied due to loss of follow up which is a limitation in the present study. No correlation was done between both IHC markers.

CONCLUSION

Immunohistochemical staining by p63 is diagnostically reliable in identifying basal cells in prostatic needle biopsies and TURP specimens. p63 is a valuable tool with high sensitivity in differentiating BPH from prostatic carcinoma.

The decreased or absent stromal staining of calponin which indicates a reactive stroma in malignancy can be used alone or in conjunction with p63 for confirmation of diagnosis of prostatic carcinoma. In future, specific studies will be directed towards identifying specific markers of reactive stroma which will aid in predicting the rate of cancer progression and possibility of recurrence. The future holds promise for novel therapeutic drugs targeting specific components of reactive stroma.

REFERENCES

- Quatani FA, Atta IS, Mady EA. p63 and Cyclin D1 Expression in Benign Prostatic Hyperplasia versus prostatic Adenocarcinoma: A Clinicopathologic, radiological and Immunohistochemical study. *IJHS*. 2014 Oct;2:305-20
- Baig MK, Hassan U, Mansoor S. Role of p63 in differentiating morphologically ambiguous lesions of prostate. *J Coll Physicians Surg Pak*. 2012 Dec; 22(12):773-77.
- Grisanzio C, Signoretti S. p63 in prostate biology and pathology. *J. Cell. Biochem*. 2008 Apr 1;103(5):1354-68.
- John R Srigley .Benign mimickers of prostatic adenocarcinoma, *Modern Pathology* 17,2004 Feb 13:328-48.
- Jain S, Saxena S, Kumar A. Epidemiology of prostate cancer in India. *Meta Gene*. 2014 Aug 29;2:596-60
- Tuxhorn JA, Ayala GE, Smith MJ, Smith VC, Dang TD, Rowley DR. Reactive stroma in human prostate cancer: induction of myofibroblast phenotype and extracellular matrix remodeling. *Clin. Cancer Res*. 2002 Sep;8(9):2912-23.
- Jennifer A.Tuxhorn, Gustavo.E.Ayala Reactive stroma in prostate cancer progression. *J.Uro* 2001; Dec 166(6) :2472-83
- Ronnov-Jessen L, Petersen OW, Bissell MJ. Cellular changes involved in conversion of normal to malignant breast: importance of the stromal reaction. *Physiological Reviews*. 1996 Jan 1; 76(1):69-125.
- Häussler O, Epstein JI, Amin MB, Heitz PU, Hailemariam S. Cell proliferation, apoptosis, oncogene, and tumor suppressor gene status in adenosis with comparison to benign prostatic hyperplasia, prostatic intraepithelial neoplasia, and cancer. *Human Pathology*. 1999 Sep 1;30(9):1077-86.
- Signoretti S, Waltregny D, Dilks J, Isaac B, Lin D, Garraway L, et al. p63 Is a Prostate Basal Cell Marker and Is Required for Prostate Development. *Am J Pathol*. 2000 Dec; 157(6):1769-75.
- Weinstein MH, Signoretti S, Loda M. Diagnostic utility of immunohistochemical staining for p63, a sensitive marker of prostatic basal cells. *Mod. Pathol*. 2002 Dec; 15(12):1302-08.
- Moazzem Hossain M, Wang X, Bergan RC, Jin J-P. Diminished expression of h2-calponin in prostate cancer cells promotes cell proliferation, migration and the dependence of cell adhesion on substrate stiffness. *FEBS Open Bio*. 2014 Jun 24; 4:62-36.
- Epstein JI, Allsbrook WC, Amin MB, Egevad LL, ISUP Grading Committee. The 2005 International Society of Urological Pathology (ISUP) Consensus Conference on Gleason Grading of Prostatic Carcinoma. *Am. J. Surg. Pathol*. 2005 Sep; 29(9):1228-42.
- Gleason DF, Mellinger GT. Prediction of prognosis for prostaticadenocarcinoma by combined histological grading and clinical staging. *J. Urol*. 1974 Jan;111(1):58-64.
- Humphrey PA. Gleason grading and prognostic factors in carcinoma of the prostate. *Mod. Pathol*. 2004 Mar;17(3):292-306.
- Shiran MS, Tan GC, Sabariah AR, Rampal L, Phang KS. p63 as a complimentary basal cell specific marker to high molecular weight-cytokeratin in distinguishing prostatic carcinoma from benign prostatic lesions. *Med. J. Malaysia*. 2007 Mar; 62(1):36-39.
- Ng VW, Koh M, Tan SY, Tan PH. Is triple immunostaining with 34beta E12, p63, and racemase in prostate cancer advantageous? A tissue microarray study. *Am. J. Clin. Pathol*. 2007 Feb;127(2):248-53.
- Dhillon PK, Barry M, Stampfer MJ, Perner S, Fiorentino M, Fornari A, et al. Aberrant Cytoplasmic Expression of P63 and Prostate Cancer Mortality. *Cancer Epidemiologic Biomarkers Prev*. 2009 Feb;18(2):595-600.
- Osunkoya A, Hansel D, Sun X, Netto GJ, Epstein JI. Aberrant diffuse expression of p63 in adenocarcinoma of the prostate on needle biopsy and radical prostatectomy: report of 21 cases. *Am J Surg Pathol*. 2008;32(3):461-67.

PARTICULARS OF CONTRIBUTORS:

- Associate Professor, Department of Pathology, Omandurar Medical College, Chennai, Tamil Nadu, India.
- Postgraduate, Department of Pathology, Government Chengalpattu Medical College, Ernakulam, Tamil Nadu, India.
- Head of the Department, Department of Pathology, Government Chengalpattu Medical College, Chengalpattu, Tamil Nadu, India.

NAME, ADDRESS, E-MAIL ID OF THE CORRESPONDING AUTHOR:

Dr. S Sreela,
Mani Mandir, Chalilpadam, Kombara, N.A.D P.O, Aluva, Ernakulam-683108, Kerala, India.
E-mail: sreela_la@yahoo.co.in

FINANCIAL OR OTHER COMPETING INTERESTS: None.

Date of Submission: **Jun 05, 2018**
Date of Peer Review: **Sep 06, 2018**
Date of Acceptance: **Dec 31, 2018**
Date of Publishing: **Jan 01, 2019**