

# Breast Hamartoma: A Rare Case Report

PREETI RAI<sup>1</sup>, REEMA BHUSHAN<sup>2</sup>, RITI SINHA<sup>3</sup>, RENU SINGH<sup>4</sup>

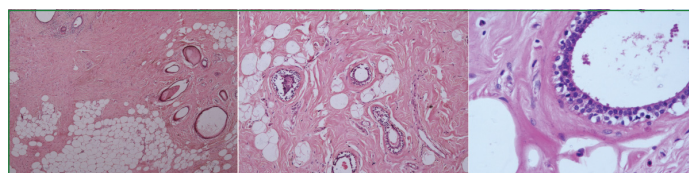
## ABSTRACT

Hamartomas of the breast are rare benign lesion which are often seen in females more than 35 years of age. Here, we present a case report of a 32-year-old female with progressively enlarging left sided breast lump which was clinically suspected to be phyllodes tumour while fine needle aspiration cytology suspected it to be fibroadenoma. A final diagnosis of hamartoma of breast was given on histological examination of the excised lump. Hence, histological examination of this entity is important as it can mimic other lesions of breast clinicoradiologically.

**Keywords:** Adenomyoepithelioma, Adipose tissue, Fibroadenoma, Fibrous tissue, Phyllodes

## CASE REPORT

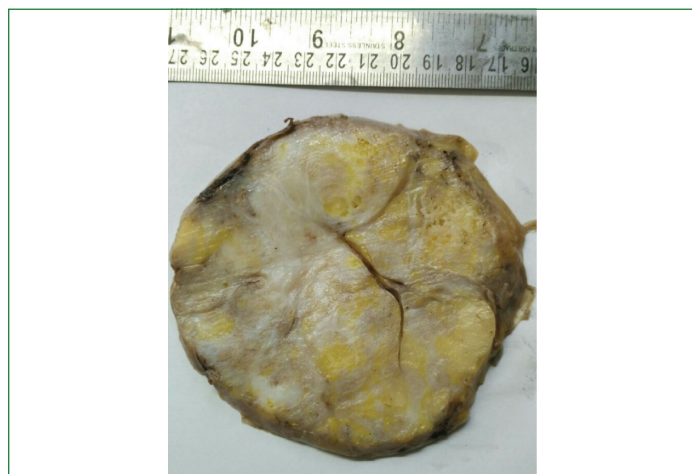A 32-year-old female presented with progressively enlarging left sided breast lump since six years. On local examination, a 10x8 cm, non tender, lobulated firm lump with bosselated surface was noted in left breast. It was not fixed to underlying structures. Overlying skin appears tense and shiny. Due to the bosselated appearance, clinical diagnosis of phyllodes tumour was made. There was no family history of lump in breast in the mother or other female relatives. The patient does not have any significant past medical history and was not undergoing any treatment or any hormonal therapy. Mammographic examination showed a 9x8x4 cm circumscribed and non homogeneous mass in left breast with low density areas, suggestive of adenomatous lesion. Fine needle aspiration cytology showed monolayered sheets of benign ductal epithelial cells admixed with benign myoepithelial cells with scant amount of stroma and bare bipolar nuclei in the background. The diagnosis of benign breast lesion suggestive of fibroadenoma was made. Lumpectomy was done. Grossly, the tumour was 9x8x4 cm and was well circumscribed and encapsulated. Serial sections of the tumour appear grey white with yellowish areas [Table/Fig-1]. Microscopic examination from the mass show well circumscribed lesion comprising of scattered lobules of mammary glands separated by dense fibrous tissue admixed with mature adipose tissue [Table/Fig-2]. A final diagnosis of hamartoma of breast was given. Patient does not have any recurrence of the mass after six months follow-up.



**[Table/Fig-2 (a,b,c)]:** Microscopy shows mass composed of lobules of mammary glands separated by dense fibrous tissue with admixture of mature adipose tissue. (a- H&E, 10X; b- H&E, 10X; c- H&E, 40X). (images from left to right)

## DISCUSSION

Hamartomas of the breast are rare benign lump, also known by the names of fibroadenolipoma, lipofibroadenoma or adenolipomas [1]. Arrigoni MG et al., described the first case of breast hamartomas in 1971 which both clinically and grossly resembled fibroadenomas [2]. The frequency of the tumour in the literature is reported to be between 0.04%-1.15% [3,4]. It has been reported to account for 4.8% of all benign breast tumours [4,5] by few studies. The majority of these lesions occur in females more than 35-year-old. However, Tele JS et al., reported breast hamartoma in a 23-year-old female which rapidly increased in size during her pregnancy [6]. Their study further concluded that both epithelial and stromal components of breast hamartoma express hormone receptors [6,7] and hence, the size increased tremendously during pregnancy. Hamartomas are composed of glandular, adipose and fibrous tissue in abnormal proportions as well as malformations. Breast hamartoma is often underdiagnosed as sonographic and fine needle aspiration findings are not conclusive to suspect a diagnosis of hamartoma. Same occurred in the present case also. Its diagnosis is often missed due to its resemblance to other benign lesions and with physiological changes of the breast. Incidence of malignancy has been reported in approximately 0.1% cases of hamartomas [8]. Hence, histopathological examination of excised lump is important and it helps in confirming the diagnosis. Histologically, the tumour is composed of mature adipose tissue and mammary parenchyma in mixed proportion having a surrounding pseudocapsule. Lobules and ducts in the tumour are structurally normal without any proliferative activity. Breast hamartoma should be differentiated from other breast lesions like fibroadenoma, nonspecific fibromatosis of breast and adenomyoepithelioma [9]. Fibroadenoma of the breast generally occurs at a younger age, generally between 20 and 35 years. Microscopically in fibroadenomas, the epithelial component shows proliferation of ducts in intracanalicular or a pericanalicular pattern. Lobules are distinctly rare. Moreover, dense hyalinized connective tissue, which is commonly present in hamartomas,



**[Table/Fig-1]:** Gross-encapsulated well circumscribed mass, cut section grey white with yellowish areas.

is uncommon in fibroadenomas [10]. Fibromatosis of the breast is a more cellular and show proliferation of fibrous tissue around the ducts and lobules. Moreover, it has infiltrating margin. Breast hamartomas on the other hand are well-circumscribed lesions [11]. Adenomyoepithelioma is a biphasic (epithelial/myoepithelial) breast neoplasm with expansion of the myoepithelial component. Myoepithelial component shows positivity for keratin, p63, smooth muscle actin in adenomyoepithelioma. Histologically, it shows tubules without lobules without any admixed fat [12]. Phyllodes tumour (cystosarcoma phyllodes) shows a hypercellular stroma along with foci of irregular intracanalicular growth. Mitoses are often present in phyllodes tumours, while hamartomas of the breast have no or extremely rare mitoses [13]. Tse GMK et al., found 37.8 years as the median age of patients with benign hamartoma. He also reported that the malignancy within hamartoma may occur in the median age of 58.2 years. Studies have proposed that carcinoma arising in a breast hamartoma is a coincidental finding [10]. Other lesions which are found to be seen in patient with breast hamartoma are usual ductal hyperplasia, apocrine metaplasia, calcification, stromal giant cells and adenosis [14]. Tse GMK et al., reviewed 25 cases of breast hamartoma. In their series of cases, all hamartomas demonstrated good tumour demarcation along with fibrous tissue condensation. Adipose tissue was noted in all with interlobular fibrosis in 21 out of 25 cases. Associated findings that were seen in addition to hamartoma were benign epithelial hyperplasia, pseudo-angiomatous stromal hyperplasia, apocrine metaplasia, calcification, stromal giant cells, and adenosis. Two cases in their series out of 25 cases showed coexisting ductal carcinoma in situ within the hamartoma [15]. Recurrence rate of hamartomas is reported in literature to be around 8%. Studies showed that hamartoma breast recurrence likely represent multifocal disease rather than true recurrence [6,16]. However, no recurrence was seen in the present case after six months of follow up. Surgical removal is the curative method for breast hamartomas.

## CONCLUSION

Breast hamartoma are rare benign lesion and appear as 'breast within a breast'. Due to different differential diagnosis of breast lump, a high degree of suspicion should be considered for this entity. FNAC and core biopsy are not useful in making the diagnosis,

thus, excision and histological examination are necessary to avoid misdiagnosis. As reports of malignancies have been reported which may arise from the different element of the lesion, hence, excision is the treatment of choice.

## REFERENCES

- [1] Guray M, Sahin AA. Benign breast diseases: classification, diagnosis, and management. *Oncologist*. 2006;11:435-49.
- [2] Arrigoni MG, Dockerty MB, Judd ES. The identification and treatment of mammary hamartoma. *Surg Gynecol Obstet*. 1971;133:577-82.
- [3] Hessler C, Schnyder O, Ozello L. Hamartoma of the Breast: Diagnostic Observation of 16 Cases. *Radiology*. 1978;126:95-98.
- [4] Barbaros U, Deveci U, Erbi YL, Budak D. Breast hamartoma: a case report. *Actachirbelg*. 2005;105:658-59.
- [5] Charpin C, Mathoulin MP, Andrac L. Reappraisal of breast hamartomas. a morphological study of 41 cases. *Pathol Res Pract*. 1994;190:362-71.
- [6] Tele JS, Patil NJ, Bhosale S, Gupta SO. An unusual case of huge hamartoma of breast in a 23 year old female: a case report. *Int J Res Med Sci*. 2018;6:2172-75.
- [7] Lakhani S, Ellis I, Schnitt S, Tan PH, Van de Vijver M. (Eds.). WHO classification of tumours of the Breast. WHO classification of tumours, WHO Press, Geneva, Switzerland. 2012; 4:147.
- [8] Lee EH, Wylie EJ, Barke AG, Bastiaan DBW. Invasive ductal carcinoma arising in a breast hamartoma: two case reports and a review of the literature. *Clin Radiol*. 2003;58:80-83.
- [9] Sonmez FC, Guzin Z, Yildiz P, Tosuner Z. Hamartoma of the breast in two patients: A case report. *Oncology Letters*. 2013;6:442-44.
- [10] Cazorla S, Arentz C. Breast hamartomas – Differential consideration in slow developing breast asymmetry. *JPRAS Open*. 2015;(3):17-21.
- [11] Ali M, Fayemi AE, Braun EV, Remy R. Fibromatosis of the breast. *Am J Surg Pathol*. 1979;3:501-05.
- [12] [Surgpathcriteria.stanford.edu](http://surgpathcriteria.stanford.edu). (2018). Printable - Adenomyoepithelioma of the Breast - Surgical Pathology Criteria - Stanford University School of Medicine. [online] Available at: <http://surgpathcriteria.stanford.edu/breast/adenomyoepitheliomabr/printable.html> [Accessed 27 Oct. 2018].
- [13] Daya D, Trus T, D'souza TJ, Minuk T, Yemen B. Hamartoma of the Breast, an Underrecognized Breast Lesion A Clinicopathologic and Radiographic Study of 25 Cases. *Am J Clin Pathol*. 1995;103:685-89.
- [14] Moinfar F. Mesenchymal lesions/tumours. In: *Essentials of Diagnostic Breast Pathology*. Springer-Verlag, Heidelberg 2007:383.
- [15] Tse GMK, Law BKB, Ma TFK, Chan ABW, Pang LM, Chu WCW, et al. Hamartoma of the breast: a clinicopathological review. *J Clin Pathol*. 2002;55(12):951-54.
- [16] Tavassoli F, Eusebi V. Tumours of the mammary gland. *AFIP Atlas Tumour Pathol*. 2009;4:21-35.

### PARTICULARS OF CONTRIBUTORS:

1. Professor, Department of Pathology, Lady Hardinge Medical College, New Delhi, Delhi, India.
2. Senior Resident, Department of Pathology, Lady Hardinge Medical College, New Delhi, Delhi, India.
3. Associate Professor, Department of Pathology, Gujarat Adani Institute of Medical Sciences, Gujarat, India.
4. Postgraduate Student, Department of Pathology, Lady Hardinge Medical College, New Delhi, Delhi, India.

### NAME, ADDRESS, E-MAIL ID OF THE CORRESPONDING AUTHOR:

Dr. Reema Bhushan,  
1113, Sector-4 RK Puram, New Delhi-110022, Delhi, India.  
E-mail: [dreems25@gmail.com](mailto:dreems25@gmail.com)

Date of Submission: **Sep 16, 2018**

Date of Peer Review: **Oct 11, 2018**

Date of Acceptance: **Nov 24, 2018**

Date of Publishing: **Jan 01, 2019**

FINANCIAL OR OTHER COMPETING INTERESTS: None.