

Isolated Langerhans Cell Histiocytosis of Thyroid-Masquerading as a Thyroid Neoplasm - A Rare Case Report

SHUSHRUTA MOHANTY, RADHARANI PANDA, APARAJITA MISHRA, KALPALATA TRIPATHY

ABSTRACT

Langerhans Cell Histiocytosis (LCH) is a rare neoplastic disease of unknown etiology characterized by oligoclonal proliferation of langerhans cells with a varying incidence rate of 4-5.4 per 1 million individuals. LCH occurs in localised and multifocal forms. LCH lesions were first described in the year 1893, they are composed of large histiocytes with abundant cytoplasm intermixed with lymphocytes and eosinophils. Diabetes insipidus is the most common endocrinological abnormality of LCH. Other manifestations such as hypothalamic/pituitary axis disturbance and anterior pituitary deficiency can occur resulting in secondary or tertiary hypothyroidism.

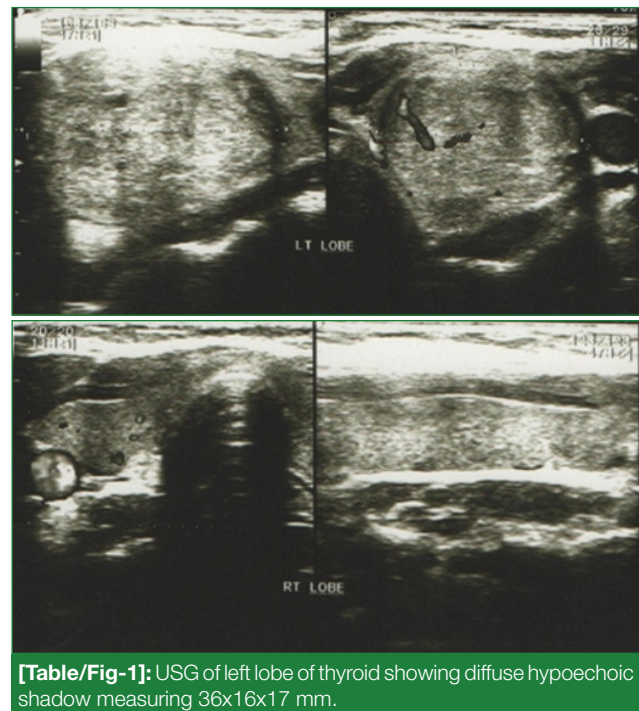
Cases of LCH with isolated thyroid involvement are very rare. We present a case of LCH, in a 42-year-old female who had a

nodular thyroid swelling since one and a half year with euthyroid status. Total thyroidectomy specimen was received with a clinical diagnosis of thyroid neoplasm. Histopathology revealed langerhans histiocytes both mononucleated and multinucleated with prominent nuclear grooves, accompanied by good number of eosinophils and lymphocytes. Histopathology diagnosis of LCH was given supported by IHC S-100 and CD 1a positivity. Since, it's a rare entity it needs to be distinguished from its closer mimics non Hodgkin's lymphoma and Rosai Dorfman's disease. Treatment of choice is surgical resection, but there is no evidence of improved outcome on usage of adjuvant chemoradiotherapy for primary thyroid LCH post resection. So, more case reports and articles are recommended to access treatment regimen for better outcome.

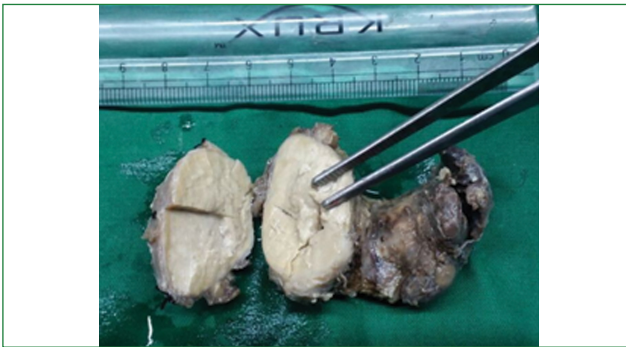
Keywords: Multinucleated cells, Nuclear grooving, Thyroidectomy

CASE REPORT

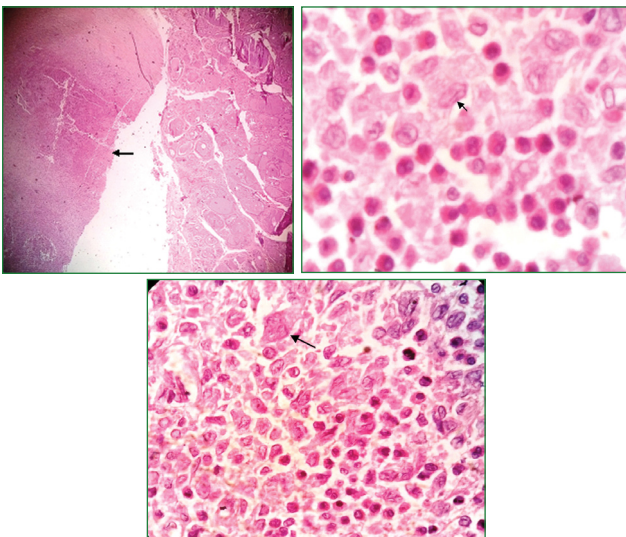
A 42-year-old female presented with an indolent thyroid swelling since one and half year. On investigation complete haemogram was normal. Thyroid profile was also normal. Patient had no complains of diabetes insipidus. Patient had no history of any thyroidal pain or obstructive symptoms. Physical examination revealed diffuse firm, non-tender, mobile nodule on the left lobe of thyroid. USG showed diffuse hypoechoic thyroid with dimension 36x16x17 mm on the left lobe [Table/Fig-1]. Radiologically, was diagnosed as thyroid neoplasm. Gross received was a thyroidectomy specimen with attached normal thyroid measuring 7x3x2 cm. Cut section of the nodule showed homogenous grey white areas. Sections were given from the lesion along with the normal thyroid. On histopathology we found characteristic morphology with dyscohesive mononucleated and multinucleated cells with moderate to abundant eosinophilic cytoplasm, irregular convoluted nuclei and prominent nuclear grooving admixed with varying proportions of eosinophils, and lymphocytes. There were areas showing compressed normal thyroid tissue. Therefore, a diagnosis of LCH of thyroid was made on the basis of biopsy which was further confirmed by IHC- S100 and CD 1a positivity [Table/Fig-2-4].



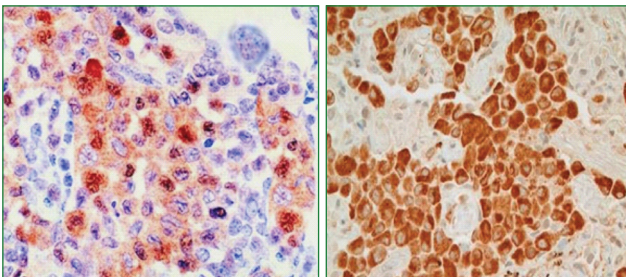
[Table/Fig-1]: USG of left lobe of thyroid showing diffuse hypoechoic shadow measuring 36x16x17 mm.



[Table/Fig-2]: Thyroidectomy specimen measuring 7x3x2 cm. Cut section showing greyish white mass with attached normal thyroid.



[Table/Fig-3]: a) Normal thyroid with the lesion LP 100X H&E (arrow); b) Photomicrograph HP 400X –showing histiocytes having nuclear grooving (arrow) admixed with eosinophils; c) Photomicrograph HP 400X shows presence of giant cells (arrow).



[Table/Fig-4]: a) Photomicrograph showing s100 positivity; b) Photomicrograph showing CD 1a positivity.

A follow-up study was done after four months, patient was clinically and radiologically normal and did not show any evidence of dissemination. Based on Histopathology and IHC findings a diagnosis of isolated Thyroid LCH was given.

DISCUSSION

LCH is a rare disease typically presents involving bone, skin, lung, lymphnodes and multiple sites [1]. However, LCH

involving the thyroid gland is extremely rare and there are only few reported cases as isolated involvement of thyroid by LCH [2,3].

Despite recent progress, the etiology and pathogenesis of LCH still remains unclear. William CL et al., demonstrated that LCH is a clonal proliferative disorder confirming its neoplastic nature [4].

Thyroid involvement is more common in adults and follows an indolent course. Most of them present as diffuse or multinodular enlargement of thyroid. It's important to distinguish isolated thyroid disease from multisystem disease as single organ involvement has better prognosis [5].

Due to such non specific presentation, it is easily confused with benign goiters or thyroid neoplasms. The histomorphology often mimicks Rosai Dorfman's disease and NHL. In our case the IHC staining of S100 and CD1a positivity and CD45 (was negative) helped in ruling out its closest histomorphological disease i.e., Rosai Dorfmann's disease and NHL. Therefore to arrive at correct diagnosis is quite challenging for pathologists as well as clinicians [6].

Papillary carcinomas has been reported to coexist with LCH within the thyroid gland [7]. Some cases were also reported where LCH was misdiagnosed as poorly differentiated carcinomas of thyroid.

Ultrasound and FNAC being the first diagnostic modality for the work up [8], followed by biopsy and IHC by CD1a and S-100. The disease is usually confirmed by electron microscopy which shows characteristic Birbeck's granules [9]. In our case HP finding and IHC using S-100 and CD 1a gave a clue to arrive at correct diagnosis.

Management of LCH of thyroid is controversial. Treatment of choice for primary thyroid LCH in adults is surgical resection by hemi, subtotal or total thyroidectomy where as in children is a combination of surgery and chemotherapy.

CONCLUSION

The diagnosis of LCH in thyroid is rare and challenging and a definitive diagnosis of this uncommon tumour depends on the distinctive histomorphology and IHC. LCH is currently regarded as a low grade malignancy, and can proceed to a multisystem disease, so additional investigations like whole body CT, bone scintigraphy and abdominal ultrasound should be added to investigation protocol when LCH of thyroid is suspected. An early and correct diagnosis with adequate follow-up in these cases can lead to proper management and favorable outcome.

REFERENCES

- [1] Howarth DM, Gilchrist GS, Mullan BP, Wiseman GA, Edmonson JH, Schomberg PJ. Langerhans cell histiocytosis diagnosis, natural history, management, and outcome. *Cancer*. 1999;85(10):2278-90.
- [2] Lieberman PH, Jones CR, Steinman RM, Erlandson RA, Smith J, Gee T, et al. Langerhans cell (eosinophilic) granulomatosis: a clinicopathologic study encompassing 50 years. *Am J Surg*

- Pathol. 1996;20(5):519-52.
- [3] Behrens RJ, Levi AW, Westra WH, Dutta D, Cooper DS. Langerhans cell histiocytosis of the thyroid: a report of two cases and review of the literature. *Thyroid*. 2001;11(7):697-705.
- [4] Willman CL, Busque L, Griffith BB, Favara BE, McClain KL, Duncan MH, et al. Langerhan's cell histiocytosis (histiocytosis X)—a clonal proliferative disease. *N Engl J Med*. 1994;331(3):154-60.
- [5] Hung CS, Yeh YC, Chen JC, Jung SM, Hung IJ, Lo FS. Isolated Langerhans cell histiocytosis of the thyroid in a female infant. *Eur J Pediatr*. 2007;166(11):1151-53. Epub 2007 Mar 20.
- [6] Braithe F, Kurzrock R. Case 1. Langerhans cell histiocytosis of the thyroid. *J Clin Oncol*. 2006;24(3):522-23.
- [7] Goldstein N, Layfield LJ. Thyromegaly secondary to simultaneous papillary carcinoma and histiocytosis X. Report of a case and review of literature. *Acta Cytol*. 1991;35(4):422-26.
- [8] Farrag TY, Lin FR, Cummings CW, Sciubba JJ, Koch WM, Flint PW, et al. Importance of routine evaluation of the thyroid gland prior to open partial laryngectomy. *Arch Otolaryngol Head Neck Surg*. 2006;132(10):1047-51.
- [9] Patten DK, Wani Z, Tolley N. Solitary langerhans histiocytosis of the thyroid gland: a case report and literature review. *Head Neck Pathol*. 2012;6(2):279-89.

AUTHOR(S):

1. Dr. Shushruta Mohanty
2. Dr. Radharani Panda
3. Dr. Aparajita Mishra
4. Dr. Kalpalata Tripathy

PARTICULARS OF CONTRIBUTORS:

1. Postgraduate Student, Department of Pathology, SCB Medical College, Cuttack, Odisha, India.
2. Deputy Director, Department of Pathology, ESI Hospital, Choudwar, Odisha, India.
3. Assistant Professor, Department of Pathology, SCB Medical College, Cuttack, Odisha, India.
4. Assistant Professor, Department of Pathology, SCB Medical College, Cuttack, Odisha, India.

4. Assistant Professor, Department of Pathology, SCB Medical College, Cuttack, Odisha, India.

NAME, ADDRESS, E-MAIL ID OF THE CORRESPONDING AUTHOR:

Dr. Shushruta Mohanty,
Postgraduate Student, Department of Pathology,
SCB Medical College, Cuttack-753007, Odisha, India.
E-mail: sushruta.mohanty@gmail.com

FINANCIAL OR OTHER COMPETING INTERESTS:

None.

Date of Publishing: Jan 01, 2018