

# Prader-Willi syndrome with Oculocutaneous Albinism: Anaesthetic Implications and Management

YATISH BEVINAGUDDAIAH, SHIVAKUMAR SHIVANNA, TEJESH C ANANDASWAMY, VINAYAK PUJARI S

## ABSTRACT

Prader-Willi syndrome is a rare congenital disorder characterized by obesity, hypotonia, hypogonadism and developmental delay. The genetic disorder is caused by microdeletion on chromosome 15 on the paternal chromosome. The syndrome is a 2-stage disorder with hypotonic early infantile phase and an obese childhood

phase. These individuals have abnormal physiologic response to hypoxia and hypercapnia, narrow oropharyngeal space, thick secretions and exaggerated response to sedatives posing increased anaesthetic risk. We describe the anaesthetic management of a patient with Prader-Willi syndrome where in laparoscopic orchidopexy was performed successfully under general anaesthesia.

**Keywords:** Hypogonadism, Laparoscopic orchidopexy  
Prader-Willi syndrome, Oculocutaneous albinism,

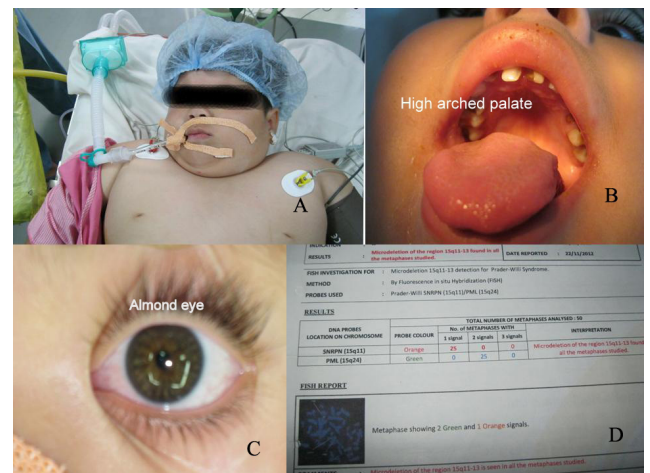
## CASE REPORT

A 7-year-old boy born of a 3<sup>rd</sup> degree consanguineous marriage presented to us for laparoscopic orchidopexy for undescended testes. The child was on syrup sodium valproate for seizure disorder for the last 4 years. The parents gave a history of snoring, though somnolence was not present. He was admitted 4 weeks prior to the surgery with complaints of weight gain and absence of gonads. On preanaesthetic examination the child was found to have fair skin, central obesity (weight 44kg, height 120 cm), thin upper lip, almond eyes, and genital hypoplasia. General physical examination revealed thin superficial veins, spontaneous bruising and manifestations of skinpicking. Airway examination revealed short neck, dental caries, high arched palate [Table/Fig-1] with limited neck extension, and mallampati grade 4. Anticipating difficult airway, x-ray neck AP and lateral and indirect laryngoscopy was ordered which was normal.

Haematological and biochemical reports were within normal limits. Fundoscopy revealed albinotic fundus and absent choroidal pigment. Echocardiography was normal except for thickened interventricular septum. Karyotyping was normal, hence fluorescence in situ hybridization (FISH) was ordered, which revealed microdeletion of 15q11-13, thus confirming the diagnosis of Prader-Willi syndrome (PWS). A detailed endocrinology workup revealed low testosterone and somatomedin levels.

Preoperatively, the child was fasted for 6 hours and premedicated with oral pantoprazole and metoclopramide.

General anaesthesia with endotracheal intubation was contemplated. EMLA cream was applied to both dorsum of foot 1hour prior to the surgery following which a 20G intravenous cannula was secured. The difficult airway cart was kept ready. In the operating room electrocardiogram (ECG), saturation (SpO<sub>2</sub>), non-invasive blood pressure (NIBP), end-tidal carbon dioxide (EtcO<sub>2</sub>) and temperature monitoring were instituted. Following preoxygenation, rapid sequence induction was performed using propofol and suxamethonium. A roll was placed under the shoulders to facilitate neck extension. Direct laryngoscopy was Cormack and Lehane grade II. Interestingly, the tracheal diameter was below the



**[Table/Fig-1]:** Figure depicting almond eyes, high arched palate and fluorescence in situ hybridization report

corresponding age group, requiring a smaller endotracheal tube (ID-5mm).

Sevoflurane 1-3% with air-oxygen mixture was used for maintenance. Intraoperative analgesia was provided with fentanyl. Top up doses of atracurium were guided by using TOF monitor and amounted to a total dose of 30mg over 2 hours. The surgical procedure lasted for 2 hours. Port site infiltration with 0.25% bupivacaine was done for post-operative analgesia. In the end when TOF had 2 responses, the patient was reversed with neostigmine and glycopyrrolate. Extubation was smooth and the patient was wide awake with adequate spontaneous respiration. The post anaesthesia recovery stay was uneventful and the patient was shifted to the paediatric ICU for further monitoring and subsequently discharged to the ward.

## DISCUSSION

PWS is a rare genetic disorder (1:15,000) caused by microdeletion on chromosome 15 on the paternal chromosome. PWS described by Prader, Labhart and Willi in 1956, is an example of imprinting disorder, the other major example being Angelman syndrome. In over 70% of PWS cases paternal deletions of 15q11-q13 is seen. The remaining 25% have maternal uniparental disomy and the rest are due to mutation in imprinting centre of chromosome 15 [1].

The syndrome is characterised by obesity, hypogonadism, hypotonia with mild to moderate mental retardation. It is a two staged disorder with hypotonic early infantile phase and an obese childhood phase. The infantile phase is characterised by failure to thrive, delayed milestones, seizures, fair skin and eyes. The later stage is characterised by obesity due to increased appetite along with behavioural changes, hypotonia, hypogonadism, dental caries, skeletal abnormalities, skin picking and spontaneous bruising [2].

These patients have a characteristic facial appearance consisting of dolichocephaly, narrow face, small mouth, thin upper lip and almond shaped eyes [3]. Additional features seen in PWS are non-insulin dependent diabetes mellitus, thick saliva, sleep disorders and impaired thermoregulation [4,5].

Mild to moderate mental retardation associated with psychological problems such as mental instability, bouts of aggressiveness, hypersomnia and hyperphagia are often seen in PWS [6]. Based on developmental screening test, our patient's IQ was calculated to be around 80.

The patients with PWS pose multiple challenges to the anaesthesiologist. The common anticipated problems being difficult airway and intubation, recurrent respiratory infections, perioperative pulmonary complications, impaired thermoregulation, obstructive sleep apnea (OSA), immature

narrow airways, mental retardation, hypotonia, and labile blood glucose [7].

Sedative premedicants should be avoided due to muscular hypotonia and hypersomnia. Antisialagogues are not advisable due to the thick oral secretions [2]. Anti-aspiration prophylaxis with H2 blockers and metoclopramide should be considered. Assurance of a NPO status can be tricky due to the food seeking and stealing behaviour, hence these patients should always be considered as full stomach irrespective of the fasting status. These patients have abnormal physiologic set point of vomiting, which reduces the tendency to vomit. A higher incidence of hiatus hernia may also be seen secondary to obesity. All these contribute to the increased risk of gastric aspiration, recurrent respiratory infections and dental caries [8]. It is also found that there is a 10-17% incidence of rumination risk of aspiration of the gastric contents in PWS [8].

The type of anaesthesia advocated depends on the degree of mental retardation. Regional anaesthesia can be difficult due to lack of patient co-operation and obesity. General anaesthesia should be performed with a secured airway, usually with an endotracheal tube (ETT). Intubation can be difficult due to obesity, micrognathia, mandibular hypoplasia, high arched palate, and dental caries. Placement of laryngeal mask airway (LMA) might not provide good seal due to high arched palate, though cases have been done successfully using LMA [9]. Fortunately, endotracheal intubation was easy in our patient albeit with a small ETT.

In view of muscular hypotonia, judicious use of muscle relaxants aided by neuromuscular monitoring is ideal. Abnormal body composition, increase in fat mass and decreased muscle mass, with some degree of neuromuscular abnormality might contribute to the hypotonia which can be seen in these patients [10]. The choice of muscle relaxant in these patients is difficult due to the above factors, though successful anaesthetic management using atracurium with neuromuscular monitoring has been reported [2,11]. Monopharmacologic general anaesthesia with only sevoflurane and without the use of muscle relaxants has also been reported [12].

It has been noted that central adrenal insufficiency affects as many as 60% of PWS patients. These patients have been shown to have normal cortisol levels in the absence of stress [13]. In our patient the serum cortisol levels were within normal limits, nevertheless we supplemented a single dose of hydrocortisone to prevent postoperative laryngospasm and bronchospasm. No episodes of hypotension were observed intraoperatively.

The patients with PWS are also prone to OSA and few patients have required reintubation in the post-operative period [14]. Preoperative polysomnogram has been advised

by few authors in patients with severe OSA. Nasal continuous Positive airway pressure (CPAP) has been shown to improve the airway obstruction seen in the post-operative period [15]. Special attention should be given to the preoperative evaluation of OSA in these patients.

## CONCLUSION

Though rare in occurrence, the patients with PWS can pose significant anaesthetic challenges mandating a thorough preoperative evaluation and management plan. The spectrum of complications such as difficult venous access, obesity, airway changes, respiratory complication, metabolic changes and OSA should be kept in mind. Our patient had PWS with undescended testis, where in laparoscopic orchidopexy was performed successfully under general anaesthesia.

## REFERENCES

- [1] J Larry Jameson, Peter Kapp. Principles of human genetics. In: Kasper, Braunwald, Fauci, Hauser, Longo, Jameson. *Harrison's principles of Internal medicine*. 16<sup>th</sup> ed. McGraw-Hill; 2005. 385-86.
- [2] Dearlove OR, Dobson A, Super M. Anaesthesia and Prader-Willi syndrome. *Paediatr Anaesth*. 1998; 8(3):267-71.
- [3] Gunay-Aygun M, Schwartz S, Heeger S, O'Riordan MA, Cassidy SB. The changing purpose of Prader-Willi syndrome clinical diagnostic criteria and proposed revised criteria. *Pediatrics*. 2001; 108(5):E92.
- [4] Hertz G, Cataletto M, Feinsilver SH, Angulo M. Sleep and breathing patterns in patients with Prader-Willi syndrome (PWS): effects of age and gender. *Sleep*. 1993; 16(4):366-71.
- [5] Di Mario FJ, Jr, Burlison JA. Cutaneous blood flow and thermoregulation in Prader-Willi syndrome patients. *Pediatr Neurol*. 2002; 26(2):130-33.
- [6] Meco BC, Alanoglu Z, Cengiz OS, Alkis N. Anesthesia for a 16 month old patient with Prader-Willi syndrome. *J Anesth*. 2010; 24: 949-50.
- [7] Peter Biro MD. Anaesthesia in a patient with Prader-Willi syndrome and severe burn injury: a case report. *J Rom Anest Terap Int*. 2011; Vol.18 Nr.2, 149-52.
- [8] Tod B. Sloan, Celia I. Kaye. Rumination Risk of Aspiration of Gastric Contents in the Prader-Willi Syndrome. *Anesth Analg*. 1991;73:492-95.
- [9] Galante D. Bilateral ultrasound TAP block in a child affected by Prader-Willi Syndrome. *Reg Anesth Pain Medicine*. 2012; 37(7): E190.
- [10] Lewis CL. Prader-Willi syndrome: a review for pediatric physical therapists. *Pediatr Phys Ther*. 2000; 12: 87-95.
- [11] Jin Young Lee, Kwang Rae Cho, Myoung Hun Kim, Kun Moo Lee, HyoJoong Kim. General anesthetic management of Prader-Willi syndrome patient undergoing middle cerebral artery-superficial temporal artery anastomosis. *Korean J Anesthesiol*. 2012 63(1): 85-86.
- [12] S. Rinaldi, L. Rizzo, A. Di Filippo, et al. Monopharmacologic general anaesthesia with sevoflurane in pediatric patient with prader-willi syndrome. *Minerva Anesthesiol*. 2002; 68:783-90.
- [13] de Lind van Wijngaarden RF, Otten BJ, Festen DA, et al. High prevalence of central adrenal insufficiency in patients with Prader-Willi syndrome. *J Clin Endocrinol Metab*. 2008; 93(5):1649-54.
- [14] Schluter B, Buschatz D, Trowitzsch E, Aksu F, Andler W. Respiratory control in children with Prader-Willi syndrome. *Eur J Pediatr*. 1997; 156:65-8.
- [15] Chi-Hao Tseng, Chit Chen, Chung-Hang Wong<sup>1</sup>, Shu-Yam Wong, Kit-Man Wong. Anesthesia for Pediatric Patients with Prader-Willi Syndrome: Report of Two Cases. *Chang Gung Med J*. 2003; 26:453-57.

### AUTHOR(S):

1. Dr. Yatish Bevinaguddaiah.
2. Dr. Shivakumar Shivanna
3. Dr. Tejesh C Anandaswamy
4. Dr. Vinayak Pujari S

### PARTICULARS OF CONTRIBUTORS:

1. Assistant Professor, Department of Anaesthesiology, M S Ramaiah Medical College and Hospitals, Bangalore, India.
2. Professor, Department of Anaesthesiology, M S Ramaiah Medical College and Hospitals, Bangalore, India.
3. Associate Professor, Department of Anaesthesiology, M S Ramaiah Medical College and Hospitals, Bangalore, India.

4. Associate Professor, Department of Anaesthesiology, M S Ramaiah Medical College and Hospitals, Bangalore, India.

### NAME, ADDRESS, E-MAIL ID OF THE CORRESPONDING AUTHOR:

Dr. Shivakumar Shivanna,  
Professor, Department of Anaesthesiology, Critical Care and Pain, MS Ramaiah Medical College and Hospitals, Bangalore-560043, India.  
Email: shivanna03@gmail.com  
Ph: 00919611988538

### FINANCIAL OR OTHER COMPETING INTERESTS:

None.

Date of Publishing: Jun 30, 2014